

Nursing

*AACN-ACCNS-AG-Adult-Gero
CNS Wellness through Acute Care*

Questions And Answers PDF Format:

**For More Information – Visit link below:
<https://www.certsgrade.com/>**

Version = Product



Latest Version: 6.0

Question: 1

Nurse Jennifer is caring for an adult patient in the intensive care unit who needs arterial line monitoring. Suddenly, the patient develops sepsis and tenderness at the insertion site. Aside from antibiotics administration, Nurse Jennifer should:

- A. Exchange the arterial line and catheter with the seldinger technique
- B. Remove the catheter and replace it with a new one, utilizing a different site
- C. Replace the continuous flush, transducer, and pressure tubing
- D. Apply Povidone iodine at the puncture site

Answer: B

Explanation:

Aside from antibiotics administration, the nurse should remove the catheter and replace it with a new one, utilizing a different site. Do not use guide wire assisted catheter exchange whenever catheter-related infection is documented. If catheter-related infection is suspected, but there is no evidence of local catheter-related infection, remove the existing catheter and insert a new catheter over a guide wire. Send the removed catheter for culture. Leave the newly inserted catheter in place if the catheter culture result is negative. If the catheter culture indicates colonization or infection, remove the newly inserted catheter and insert a new catheter at a different site.

Question: 2

An electrician was brought to the Emergency room by his coworkers and was admitted with a possible myocardial infarction. The patient is experiencing severe chest pain. He is diaphoretic and his pulse is 115 beats per minute. The nurse should immediately:

- A. Notify the doctor and administer morphine as ordered
- B. Give the ordered nitroglycerine until pain subsides
- C. Obtain blood pressure and get the electrocardiogram
- D. Administer oxygen at 4-6 L/min

Answer: A

Explanation:

If a patient became diaphoretic and pulse is above normal range, then notify the doctor and administer morphine as ordered because the myocardial infarct maybe extending; the patient's symptoms require prompt medical intervention and pain relief. Other options can be done after except for the nitroglycerine, as it does not relieve pain in myocardial infarction.

Question: 3

The nurse at the unit is assessing a patient. She alerted the attending physician that the patient is in cardiogenic shock. Which of the following is an indication that a patient suffers from this condition?

- A. Decreased urine output
- B. Increased body temperature
- C. Decreased heart rate
- D. Increased blood pressure

Answer: A

Explanation:

An indication that a patient suffers from cardiogenic shock is decreased urine output. Other indicators of cardiogenic or hypovolemic shock include: low blood pressure, weak and rapid heart rate, cold and clammy skin, and cyanosis.

Question: 4

A 36-year-old male admitted to the hospital with a diagnosis of sub-arachnoid hemorrhage presents symptoms like aphasia and hemiparesis. The nurse is aware that these neurologic deficits, which may be present immediately after a sub-arachnoid hemorrhage, are primarily due to:

- A. Electrolyte imbalances
- B. Tissue necrosis
- C. Vascular spasms
- D. Profound blood loss

Answer: C

Explanation:

The nurse is aware that these neurologic deficits, which may be present immediately after a subarachnoid hemorrhage, are primarily due to vascular spasms. In an attempt to stop the bleeding, adjacent arteries constrict; this in turn results to ischemia that is responsible for the neurologic deficits.

Question: 5

A nurse is observing a patient with a pulmonary artery catheter in place. On the second day, the nurse observes a right ventricle waveform from the distal catheter port. What would be the most appropriate nursing action?

- A. Switch monitoring lines to the proximal port of the catheter
- B. Inflate the balloon with 1.5 ml air and advance the catheter
- C. Advance the catheter 10 cm with the balloon deflated

D. Leave in right ventricle, you can still get pulmonary artery systolic pressure from right ventricle

Answer: B

Explanation:

Appropriate action if there is a right ventricle waveform from the distal catheter port should be to inflate the balloon with 1.5 ml air to make a soft tip. Then, advance the catheter until pulmonary artery wedge waveform appears and deflate the balloon. Check the waveform to assure it is in the pulmonary artery. You do not want to insert the catheter deflated because the hard catheter tip may lodge in and damage the right ventricle or pulmonary artery wall.

Question: 6

Nurse Jenny suspects that one of the admitted patients suffers from an organic heart murmur. Nurse Jenny is aware that the murmur is probably a defect in the:

- A. Mixing of blood
- B. Coronary arteries
- C. Action of the valves
- D. Heart conduction system

Answer: C

Explanation: An organic heart murmur is caused by a defect in the action of heart valves like stenosis or regurgitation. Murmurs are not related to blood oxygenation, ability to pump, or capacity of coronary arteries.

Question: 7

Kelly, a 32-year-old college professor, was seen at the clinic. The doctor said that she is probably suffering from torsade des pointes. A 12-lead ECG tracing showed that she has a prolonged QT interval. During history taking, the nurse learns that she has a history of family deafness, previously had hypokalemia, and has likely used what medication?

- A. Anti arrhythmics
- B. Anti diabetic agents
- C. Anti tubercular
- D. Anti anemic medications

Answer: A

Explanation:

The patient likely took anti arrhythmics. Torsades des pointes is rarely associated with congenital long-QT syndrome and mostly associated with drug administration and electrolyte imbalances. Several

antiarrhythmic, anti-infective, anti-psychotics might trigger TdP by blocking specific potassium channels in the myocyte membrane. Their effect reduces the outward potassium current called I_{Kr}. Inhibition of this major re-polarizing potassium current participates in prolongation of the action potential in the ventricular myocardium and this leads to the clinical finding of QT interval prolongation.

Question: 8

Nurse Betty is caring for an adult patient who is admitted with a spinal cord injury. Betty is aware that a patient is developing autonomic dysreflexia if the patient has:

- A. Absence of sweating
- B. Pyrexia and shock
- C. Flaccid paralysis and numbness
- D. Bradycardia and paroxysmal hypertension

Answer: D

Explanation:

Betty is aware that a patient is developing autonomic dysreflexia if the patient has bradycardia and paroxysmal hypertension. These signs occur as a result of exaggerated autonomic response. Once autonomic dysreflexia is identified, immediate medical intervention should be initiated to prevent life threatening complications.

Question: 9

Channing, a 34-year-old farmer who experiences severe chest pain, is brought to the emergency room. When assessing the ECG tracing, the nurse concludes that Channing is experiencing premature ventricular contractions. Which of the following abnormalities would support this conclusion?

- A. Regular rhythm; >100 beats per minute; normal P wave; normal QRS complex
- B. Irregular rhythm; absent P wave; wide and distorted QRS complex
- C. Regular rhythm; 100-250 beats per minute; absent P wave; wide and distorted QRS complex
- D. Regular rhythm; abnormally shaped P wave; normal QRS complex

Answer: B

Explanation:

Abnormalities that would support the conclusion is irregular rhythm; absent P wave; wide and distorted QRS complex. Premature Ventricular Contractions is characterized by a premature, wide, distorted QRS complex with the P wave and P-R interval buried in the distorted QRS complex resulting in an irregular rhythm. It originates in an ectopic focus in the ventricles.

Question: 10

An electrocardiogram is ordered for Marilyn, a 42-year-old customer service representative who is complaining of chest pain. What would be an early finding in the lead over an infarcted area?

- A. Absent P wave
- B. Absent Q wave
- C. Elevated ST segment
- D. Flat T wave

Answer: C

Explanation:

An early finding in the lead over an infarcted area is an elevated ST segment. It will be an early typical finding after a myocardial infarction, which is caused by the alteration in the contractility of the heart.

Question: 11

The physician discusses the case of a patient inside the patient's room. The doctor asks the patient if she ever had an illness that would predispose her to having a heart murmur. The nurse is aware that one of these predisposing illnesses is:

- A. Mononucleosis
- B. Rheumatic fever
- C. Infectious hepatitis
- D. Mumps

Answer: B

Explanation:

The nurse is aware that one predisposing factor would be those patients who have had rheumatic fever; they often have heart valve problems, such as mitral stenosis, when they grow older. This case is common in tropical countries.

Question: 11

The physician discusses the case of a patient inside the patient's room. The doctor asks the patient if she ever had an illness that would predispose her to having a heart murmur. The nurse is aware that one of these predisposing illnesses is:

- A. Mononucleosis
- B. Rheumatic fever
- C. Infectious hepatitis
- D. Mumps

Answer: B

Explanation:

The nurse is aware that one predisposing factor would be those patients who have had rheumatic fever; they often have heart valve problems, such as mitral stenosis, when they grow older. This case is common in tropical countries.

Question: 12

Benita, a 65-year-old banker, was admitted to the unit due to pyrosis, dyspepsia, and difficulty swallowing. Based on the symptoms presented, the clinical nurse specialist might suspect:

- A. Gastric Ulcer
- B. Hiatal hernia
- C. GERD
- D. Esophagitis

Answer: C

Explanation:

Based on the symptoms presented, the clinical nurse specialist might suspect GERD. It is the backflow of gastric or duodenal contents into the esophagus caused by incompetent lower esophageal sphincter. Pyrosis or heartburn, dyspepsia, and dysphagia are cardinal symptoms.

Question: 13

Ralph is a 48-year-old driver who is admitted because of mild chest pain. He is 5 feet, 9 inches tall and weighs 200 pounds. He is diagnosed with a myocardial infarction. Morphine sulfate, Diazepam, and Lidocaine were prescribed. The doctor orders 8 mg of Morphine Sulfate to be given intravenously. The vial on hand is labeled 1 ml/ 10 mg. The CNS nurse should administer:

- A. 10 minims
- B. 12 minims
- C. 14 minims
- D. 16 minims

Answer: B

Explanation:

The CNS nurse should administer 12 minims, which is equivalent to 8mg Morphine sulfate. Using ratio and proportion $8 \text{ mg}/10 \text{ mg} = X \text{ minims}/15 \text{ minims}$ $10 X = 120$ $X = 12 \text{ minims}$.

Question: 14

Mr. David, a patient with CHF, has been receiving a cardiac glycoside, a diuretic, and a vasodilator drug. His apical pulse rate is 45 bpm and he is on bed rest. The clinical nurse specialist concludes that his pulse rate is most likely the result of which of the following:

- A. Cardiac glycoside
- B. Vasodilator
- C. Bed-rest
- D. Diuretic

Answer: A

Explanation:

The clinical nurse specialist will conclude that a pulse of 45 bpm is the result of a cardiac glycoside. A cardiac glycoside, such as digitalis, increases the force of cardiac contraction and decreases the conduction speed of impulses within the myocardium and slows the heart rate.

Question: 15

Mr. Davids is admitted to the hospital with a diagnosis of left-sided congestive heart failure. During an assessment, the nurse should expect to find:

- A. Dyspnea on exertion
- B. Peripheral edema
- C. Crushing chest pain
- D. Neck vein distention

Answer: A

Explanation:

During an assessment, the nurse should expect to find dyspnea on exertion. Pulmonary congestion and edema occur because of fluid extravasations from the pulmonary capillary bed, resulting in difficult breathing. Left-sided heart failure creates a backward effect on the pulmonary system that leads to pulmonary congestion.

Question: 16

Benita is a patient who is 48 hours post surgery for a repair of aortic aneurysm. The nurse should closely watch this patient because of what significant risk after the procedure?

- A. Potential alteration in renal perfusion
- B. Potential ineffective coping
- C. Potential wound infection
- D. Potential wound infection

Answer: A

Explanation:

The nurse should closely watch this patient because of a significant risk after the procedure, which is potential alteration in renal perfusion as evidenced by a decreased in urine output. The altered renal perfusion could be related to renal artery embolism, prolonged hypotension, or prolonged aortic crossclamping during the surgery.

Question: 17

The clinical nurse specialist notes that patient Benita has lipid abnormalities. The nurse is aware that one of the following is a risk for developing atherosclerosis:

- A. High levels of high density lipid cholesterol
- B. Low concentration triglycerides
- C. High levels of low density lipid cholesterol
- D. Low levels of low density lipid cholesterol

Answer: C

Explanation:

The nurse is aware that a risk for developing atherosclerosis is having a high level of low density lipid cholesterol (LDL). This type of cholesterol is not broken down into the liver, but is deposited into the wall of the blood vessels.

Question: 18

Mr. Hoffman, a firefighter, was admitted to the unit due to an accidental burn sustained after a rescue. The patient sustained thoracic burns and smoke inhalation and therefore, is at high risk for impaired gas exchange.

Nursing interventions for this patient would include all of the following except for:

- A. Suctioning the airway PRN
- B. Repositioning from side to side every 2 hours
- C. Maintaining the patient in supine position with the head of the bed elevated
- D. Providing humidified oxygen as prescribed

Answer: C

Explanation:

Nursing interventions should not include maintaining the patient in supine position with the head of the bed elevated, as this will ultimately lead to atelectasis and possible pneumonia. Nurses should utilize aggressive pulmonary measures to prevent respiratory complications in the patient who has impaired gas exchange as a result of a burn injury.

Question: 19

A clinical nurse specialist assesses the carbon monoxide level of a patient following a burn injury and notes that the level is 43%. Based on this level, which finding would the nurse expect to observe during the assessment of the patient?

- A. Flushing and headache
- B. Dizziness and vomiting
- C. Tachycardia and tachypnea
- D. Coma

Answer: C

Explanation:

During the assessment, a nurse would expect to observe tachycardia and tachypnea if the carbon monoxide level is between 41% - 50%. A level between 5 to 10% would cause impaired visual acuity; 11 to 20% flushing and headache; 21 to 30% nausea and impaired dexterity; 31 to 40% vomiting, dizziness, and syncope; and greater than 50% coma and death.

Question: 20

A clinical nurse specialist is caring for a hypertensive adult male patient who is admitted at the hospital. The physician ordered verapamil to decrease blood pressure. After several days of taking the medications, it is noted that the patient is experiencing toxicity. What medication should a nurse expect as an antidote?

- A. Acetaminophen
- B. Calcium
- C. Atropine
- D. Warfarin









Answer: B

Explanation:

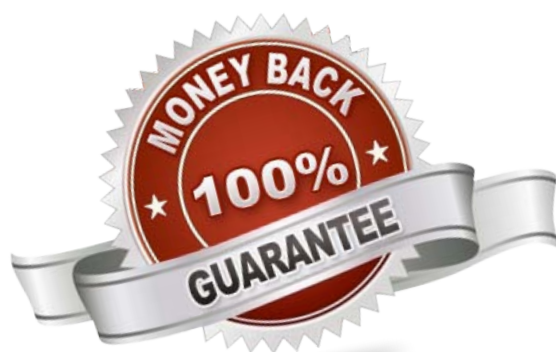
The nurse should expect that calcium will be ordered as an antidote for verapamil toxicity. The specific antidote for overdose from verapamil, or any other calcium channel blocker, is calcium.

For More Information – **Visit link below:**
<https://www.certsgrade.com/>

PRODUCT FEATURES

-  **100% Money Back Guarantee**
-  **90 Days Free updates**
-  **Special Discounts on Bulk Orders**
-  **Guaranteed Success**
-  **50,000 Satisfied Customers**
-  **100% Secure Shopping**
-  **Privacy Policy**
-  **Refund Policy**

16 USD Discount Coupon Code: **NB4XKTMZ**



Visit us at <https://www.certsgrade.com/pdf/aacn-accns-ag-adult-gero/>