

Nursing

CCRN-Pediatric

American Association of Critical Care Nurses: Critical Care Registered Nurse (Pediatric)

Questions And Answers PDF Format:

For More Information – Visit link below:

<https://www.certsgrade.com/>

Version = Product



Total Questions: 150

Latest Version: 6.0

Question: 1

A patient's family informs the care team that their religious beliefs dictate that they pray for several minutes at specific times of day and request that, when possible, evaluations of their child be arranged around the prayer times. A consulting physician arrives at the patient's room to perform a nonurgent evaluation and informs the nurse that he "will not wait around for some religious ceremony." The nurse's best action in this case is to

- A. tell the physician firmly that he is being unreasonable and disrespectful.
- B. interrupt the family's prayers to tell them the consulting physician needs to do an evaluation.
- C. try to find a time that the consultant can return, which would not interfere with the family's prayers.
- D. ask the family to pray elsewhere from now on so the child's care is not interrupted.

Answer: C

Explanation:

Each family in the critical care unit arrives with their own unique collection of values, religion, culture, assumptions, education, and communication style. Often, serious acute medical illness or injury places a great strain on the patient and family's coping skills. In this setting, respect for those religious or cultural traditions that do not interfere with essential medical care can help a family get through the stress of a child's critical illness. In this case, where there is no emergent medical need, the nurse's best action is to advocate for the family's religious preferences while expressing respect for the consulting physician's time and effort.

Question: 2

The critical care nurse is taking care of a 10-year-old patient who sustained an accidental crush injury and has developed renal failure secondary to severe rhabdomyolysis. As his condition worsens, the medical team prepares to institute continuous renal replacement therapy (CRRT). All of the following statements about CRRT are true EXCEPT

- A. CRRT allows for less dramatic fluid shifts in the hemodynamically unstable patient.
- B. there is less need for anticoagulation therapy with CRRT than with other dialysis methods.
- C. young, small-sized patients are at high risk for hypothermia with the CRRT circuit than with other dialysis methods.
- D. CRRT allows for improved nutritional support in the critically ill patient since by-products of a protein-containing diet can be cleared continuously.

Answer: B

Explanation:

The healthy kidney performs multiple body functions: excretion of waste products, maintenance of electrolyte and acid—base balance, and control of total body water. Dialysis ("renal replacement therapy") is indicated in the patient who is failing other therapeutic interventions for fluid overload, hyperkalemia, metabolic acidosis, overdose/ingestion, and uremia. Intermittent hemodialysis is very effective and works rapidly but is associated with large fluid shifts and hypovolemia that is usually not well-tolerated in the critically ill patient. Continuous renal replacement therapy (CRRT) allows for more controlled removal of fluid with effective solute clearance. With CRRT, there can be more precise control of fluid status (less hypotension) and improved nutritional support since the protein load of an optimal diet can be cleared continuously. Continuous hemofiltration requires anticoagulation, which may be complicated by excessive bleeding in the critically ill patient. The risk of hypothermia associated with the extracorporeal blood flow required for CRRT is exaggerated in the young, small-sized pediatric patient.

Question: 3

A 2-year-old child is admitted to the critical care unit after an accidental submersion injury (near drowning). Eight hours after the submersion, chest x-ray reveals diffuse bilateral patchy pulmonary infiltrates, and the child's ventilator settings reveal markedly impaired pulmonary compliance with a significant oxygen requirement. Given this clinical information, the most likely explanation for this child's pulmonary status is

- A. acute respiratory distress syndrome.
- B. congestive heart failure with secondary pulmonary edema.
- C. bacterial pneumonia.
- D. dislodged endotracheal tube.

Answer: A

Explanation:

Acute respiratory distress syndrome (ARDS) is defined as bilateral lung infiltrates on chest x-ray with a $\text{PaO}_2/\text{FiO}_2$ ratio of less than 200 and no clinical evidence of elevated left atrial pressure. Clinically, ARDS is characterized by severe hypoxemia, markedly impaired pulmonary compliance, and capillary leak leading to interstitial and alveolar edema. The cascade of injury with ARDS begins with a pulmonary or systemic insult—in this case, a submersion injury. Acute respiratory distress syndrome is also frequently seen in the setting of septic shock, even in the absence of focal pulmonary infection. An increase in alveolar capillary permeability leads to protein-rich pulmonary edema, which triggers a series of inflammatory reactions, further impairing pulmonary compliance. Although bacterial pneumonia after a submersion injury can cause bilateral infiltrates with impaired oxygenation and pulmonary compliance, this degree of pulmonary impairment 8 hours after the submersion from only bacterial pneumonia is unusual. Pulmonary edema secondary to congestive heart failure results in decreased pulmonary compliance and hypoxemia but is less likely after a near-drowning event than with ARDS.

Question: 4

A 16-year-old patient is admitted to the ICU after a 16-foot fall from a tree. The patient had a computed tomography (CT) scan en route to the ICU, and a cervical collar has been placed. The CT scan was negative for bleeding, but the patient has no sensation or movement below his waist. The patient is ventilated with 35% FiO_2 via venturi mask. The patient's data are as follows:

Mental status: No loss of consciousness: patient alert and oriented x4

Heart rate: 44

Blood pressure: 79/32 mmHg

Respiratory rate: 26

Temperature: 94.7°F

Which one of following is the most likely cause of the patient's symptoms?

- A. Neurogenic shock
- B. Hypovolemic shock
- C. Subdural hematoma
- D. Anterior cord syndrome

Answer: A

Explanation:

Neurogenic shock leads to the loss of sympathetic tone as a result of a disruption or injury to the sympathetic nervous system. Patients with neurogenic shock experience altered thermoregulation and vasodilation resulting in bradycardia, hypotension, and/or poikilothermia. Hypovolemic shock results in volume loss, which usually leads to tachycardia as a compensatory mechanism for decreased blood pressure. A subdural hematoma would be the result of a head injury. The patient does not have signs or symptoms of a head injury, such as physical marks, physical impairments, or altered mental status. Patients with anterior cord syndrome will retain sensation to the affected area.

Question: 5

In the symptomatic hyperkalemic patient, the critical care nurse expects the initial treatment to include all of the following EXCEPT

- A. nebulized albuterol administration.
- B. intravenous Administration of insulin and glucose.
- C. intravenous calcium gluconate administration.
- D. hemodialysis.

Answer: D

Explanation:

Hyperkalemia is a medical emergency, requiring rapid recognition and treatment to avoid progression to fatal cardiac arrhythmia. Acute treatment is aimed at protecting the heart from the effects of hyperkalemia while facilitating renal and gastrointestinal potassium excretion and shifting potassium ions from the extracellular to intracellular space. Intravenous calcium (chloride or gluconate) does not have any effect on serum potassium levels but has a protective effect on myocardial cells by lowering their threshold potential. Calcium works rapidly but transiently; repeated doses may be required until the serum potassium has been decreased. Facilitating potassium shift into the intracellular space is accomplished with the administration of beta-2 agonists (e.g., albuterol) and intravenous insulin (given with glucose to avoid hypoglycemia). If metabolic acidosis is present, intravenous sodium bicarbonate may also be given. Agents that enhance renal (e.g., loop diuretics) and gastrointestinal (e.g., Kayexalate) potassium excretion may also be given.

Hemodialysis is an effective means of managing hyperkalemia but would not typically be available for initial treatment.

Question: 6

A 7-year-old previously healthy patient presents with a 1-day history of fever, cough, poor oral intake, and shortness of breath. Examination reveals a fatigued child in respiratory distress with a distal capillary refill time of 3 seconds. The results of an arterial blood gas are:

pH: 7.21
PCO₂: 63 mmHg
PO₂: 74 mmHg
HCO₃: 23 mEq/L

This patient's clinical condition is best characterized as

- A. respiratory acidosis with metabolic compensation.
- B. acute respiratory acidosis without metabolic compensation.
- C. mixed respiratory and metabolic acidosis.
- D. acute metabolic acidosis without respiratory compensation.

Answer: B

Explanation:

Interpreting arterial blood gases (ABGs) should be done in a systematic manner to determine the nature of a patient's acid-base abnormality. The arterial pH reveals whether the patient has an acidosis (pH < 7.35), alkalosis (pH > 7.45), or neither (pH 7.35–7.45). The PCO₂ and HCO₃ reveal whether there is an isolated respiratory or metabolic abnormality or some combination of the two. They also demonstrate whether there is any compensation for the primary abnormality. With primary metabolic derangements, the arterial pH, serum bicarbonate and PCO₂ all change in the same direction (e.g., metabolic acidosis [decreased pH] as a result of low serum bicarbonate [decreased HCO₃], leading to compensatory hyperventilation [decreased PCO₂]). With primary respiratory derangements, the arterial pH changes in the opposite direction of serum bicarbonate and PCO₂ (e.g., respiratory alkalosis [increased pH] from hyperventilation [decreased PCO₂], leading to a compensatory decrease in renal bicarbonate reabsorption [decreased HCO₃]). This patient's ABGs demonstrates a respiratory acidosis (pH < 7.35, PCO₂ > 45) without metabolic compensation (normal HCO₃). Over time, the kidney will retain bicarbonate (increased HCO₃) to buffer the acidosis and return the overall arterial pH to normal.

Question: 7

The family of a young patient with complex medical problems voices frustration that the instructions from one subspecialty service seem to be contradicted by the instructions from another subspecialty service. In this case, the nurse's best action is to

- A. advise the family to ask the subspecialists to clarify their instructions the next time they come to evaluate the patient.
- B. tell the family that they should just follow the set of instructions with which they feel most comfortable.
- C. have the patient's regular outpatient care provider try to coordinate care between the subspecialty services after discharge.

D. arrange for a care conference involving all of the major care providers and the family to clarify the treatment plan as a group.

Answer: D

Explanation:

Patients and families often feel powerless in the critical care unit because of the unfamiliar environment, challenges of attempting to understand the complexities of their child's medical care, and the stress of a serious illness or injury, all of which contribute to a feeling of confusion and helplessness. Best nursing practice emphasizes interventions that empower patients and families to learn about and participate in their child's medical care whenever possible. It is common in the patient with complicated medical issues for the recommendations and priorities of various subspecialty providers to appear contradictory and confusing, particularly for the family who is unfamiliar with critical care medicine. In this circumstance, the critical care nurse has an important role to play in assisting families to receive clear and consistent information about their child's care. A multidisciplinary care conference with family members (and nursing staff) is often the most effective way to accomplish this.

Question: 8

A 7-year-old child is accidentally struck in the head with a baseball bat swung by her older sibling. The family reports that she cried for a few seconds after being struck and then lost consciousness for several minutes. Evaluation demonstrates a lethargic, irritable girl who vomits forcefully several times during assessment. Scalp examination reveals a swelling of the left temporal area with a barely reactive dilated left pupil. Noncontrast computed tomography of the head demonstrates a left temporal skull fracture with a large, biconvex (lens-shaped) left temporal extra-axial hematoma underlying the fracture with an associated midline shift. Given this information, the most likely diagnosis is

- A. subarachnoid hemorrhage.
- B. subdural hematoma.
- C. epidural hematoma.
- D. diffuse axonal injury.

Answer: C

Explanation:

Epidural hematomas are usually caused by a focal injury to the head and often occur in association with a skull fracture. Epidural hematomas are usually caused by arterial bleeding and typically develop within minutes of injury but may continue to expand over several hours. Patients with an epidural hematoma generally experience a severe headache, vomiting, and a decreased level of consciousness. Signs of increased intracranial pressure include hypertension, altered respirations, bradycardia, and pupillary findings. This patient's dilated pupil on the side of her head injury is due to compression of the third cranial nerve by the shifted temporal lobe. Computed tomography (CT) demonstrates a lens-shaped (biconvex), extra-axial hematoma. Subarachnoid hemorrhage may be associated with trauma, but the CT scan will demonstrate blood along the falx cerebri and outer cortex. Patients with a subarachnoid hemorrhage may also have neck stiffness and fever. Subdural hematomas occur with acceleration—deceleration injuries and causes bleeding between the

dura and the cortex. Head CT scan will demonstrate a crescent-shaped, extra-axial hematoma. Diffuse axonal injury is caused by acceleration—deceleration injury and is remarkable for the contrast between a normal CT scan and a severely neurologically impaired patient.

Question: 9

A 14-year-old patient is evaluated after a 20-foot fall. Assessment reveals a spontaneously breathing patient whose right chest moves inward on inhalation and outward on exhalation. The left chest rises on inhalation and falls on exhalation. This patient's chest examination reveals a

- A. right pneumothorax.
- B. bag-mask ventilation.
- C. left flail chest.
- D. right flail chest.

Answer: D

Explanation:

Chest wall injury is common in cases of serious blunt trauma, such as occurs with falls, assault, and motor vehicle accidents. Flail chest is characterized by paradoxical movement of a segment of the chest wall with respiration from multiple fractures within the rib, involving at least two or three ribs. The flail segment is effectively separated from the rest of the chest wall by the fractures. Clinically, the flail segment moves inward during spontaneous inhalation and outward during passive exhalation, in contrast to chest wall movement with normal respiration. The flail segment itself may cause significant respiratory difficulty. Although generally internal injuries associated with the blunt trauma (e.g., pulmonary and cardiac contusions) are responsible for more significant respiratory insufficiency. This patient demonstrates right-sided flail chest, with paradoxical movement of the right chest wall during spontaneous respirations.

Question: 10

A patient has recently undergone open-heart surgery for complex congenital heart disease; he is being treated with topical antibiotics for a superficial sternal wound infection when he develops fever, tachycardia, worsening sternal pain, and purulent discharge from the wound. On the basis of this information, the critical care nurse suspects that the patient has developed which of the following complications?

- A. Mediastinitis
- B. Pulmonary embolus
- C. Bacterial endocarditis
- D. Aortic dissection

Answer: A

Explanation:

Mediastinitis describes a bacterial infection of the mediastinum, a potentially life-threatening infection that is most commonly seen after cardiac surgery. Mediastinitis may also complicate chest trauma, esophageal

perforation, or adjacent infection. which spreads to the mediastinal space. Sternal wound dehiscence is a known risk factor for the development of mediastinitis. Patients may present with fever, tachycardia, sternal wound drainage, cellulitis, and signs of hemodynamic instability. There may also be sternal instability or a sternal "click" Hamman sign is a crunching sound heard during systole with auscultation of the chest wall, which may or may not be present with mediastinitis, Purulent discharge from this patient's sternal wound with increased sternal wound pain make pulmonary embolus, aortic dissection, and bacterial endocarditis less likely than mediastinitis in this patient.

Question: 11

In caring for a patient with fulminant hepatic failure, the critical care nurse anticipates all of the following clinical features EXCEPT

- A. coagulopathy requiring vitamin K administration.
- B. hyperglycemia requiring insulin administration.
- C. altered mental status.
- D. jaundice.

Answer: B

Explanation:

Fulminant acute hepatic failure may be seen in the pediatric population without an identifiable inciting illness or infection or may be associated with autoimmune or infectious hepatitis. Manifestations of fulminant hepatic failure reflect the inability of the failing liver to perform its usual complex detoxifying and synthetic functions. Altered mental status (i.e., hepatic encephalopathy) occurs secondary to the accumulation of neurotoxic metabolites. such as ammonia. Coagulopathy occurs as the liver can no longer synthesize clotting factors. Jaundice is seen as failing hepatocytes can no longer conjugate bilirubin into its excretable water-soluble form. Hypoglycemia is commonly seen in late hepatic failure due to the disappearance of hepatic glycogen stores. Treatment is generally supportive (unless a treatable etiology is found), but a liver transplantation should be considered in patients who continue to deteriorate.

Question: 12

The clinical presentation that most likely indicates child abuse is a

- A. newborn infant with a subdural hematoma after a traumatic vaginal delivery.
- B. 2-year-old child with a clavicle fracture after reportedly falling out of bed.
- C. 3-year-old child with a symmetric, sharply demarcated scald burn after reportedly pulling a hot cup of tea onto himself.
- D. 4-year-old child with numerous bruises on the anterior lower legs.

Answer: C

Explanation:

Certain patterns of injury, particularly in association with changing caregiver stories or a delay in seeking medical care, are highly suggestive of child abuse. A significant indicator of child abuse is an injury that

was not plausibly caused by the reported mechanism. Fractures or bruising in the nonmobile infant, particularly in the absence of a plausible mechanism of injury (e.g., adult falling while holding the infant), is highly suspicious for abuse. Bruises in unusual regions in the mobile child (e.g., abdomen, perineum, buttocks) or bruises with patterns suggestive of a child being hit with certain objects, such as cords or belt buckles, should also raise suspicion. Clearly demarcated burn lines without the typical irregularities one would expect with accidental burns suggest inflicted injury. Significant head injury in association with a history of minor trauma is typical in cases of abuse. Subdural hematomas may be observed in the newborn after a traumatic delivery. Clavicle fractures are commonly seen in the setting of a minor fall and are rarely associated with abuse. Bruises over bony prominences, such as the shins, in a mobile child are not associated with abuse.

Question: 13

A 4-year-old child is in the critical care unit after a serious motor vehicle accident. The child is successfully extubated after 1 week of mechanical ventilation. Soon after extubation, the child is noted to have inspiratory stridor and mild suprasternal retractions. Oxygen saturation on room air is 96%. The child is alert and appropriately interactive with the family. Which of the following interventions is most appropriate in this clinical situation?

- A. Continued observation
- B. Oral clear fluids to ease throat irritation
- C. Reintubation
- D. Nebulized racemic epinephrine

Answer: D

Explanation:

The child described in the question has evidence of upper airway edema after prolonged intubation with mild increased work of breathing but is maintaining normal mental status and adequate oxygenation. In this case, a trial of inhaled racemic epinephrine to improve upper airway edema is reasonable given that the patient is not showing signs of respiratory failure or rapid decompensation. Oral fluids should be withheld until the patient's respiratory status has improved and the child has been observed for several hours after extubation. Reintubation is not indicated in this patient unless worsening respiratory distress, hypoxemia, or signs of respiratory fatigue develop. Given that this patient has evidence of increased work of breathing and stridor at rest, simple observation is not appropriate in this case.

Question: 14

A 4-year-old patient is admitted with a new diagnosis of Burkitt's lymphoma

- a. Forty-eight hours after chemotherapy is initiated, she develops hyperkalemia, hyperuricemia, hyperphosphatemia, and acute kidney injury. The most likely etiology of these findings is
- A. tumor lysis syndrome.
 - B. dehydration.
 - C. metastatic disease in the patient's kidneys.
 - D. rhabdomyolysis.

Answer: A

Explanation:

Tumor lysis syndrome describes a set of metabolic abnormalities that can occur with certain malignancies, particularly in the first several days after initiation of treatment. The pediatric malignancies most commonly associated with tumor lysis syndrome are Burkitt's lymphoma and T-cell leukemia. These cancers are highly responsive to chemotherapeutic agents, leading to rapid and massive tumor cell lysis. Tumor lysis syndrome is characterized by elevated serum phosphorus, leading to secondary hypocalcemia; hyperkalemia; and elevated uric acid levels, which may lead to acute oliguric renal failure. Patients presenting with a new malignancy and initiating treatment need to be closely monitored for the development of tumor lysis syndrome. Management includes aggressive management of hyperkalemia and intravenous fluid administration. Allopurinol is often given to lower serum uric acid levels, while alkalized intravenous fluid enhances renal excretion of uric acid.

Question: 15

The grandfather of a patient in the critical care unit is alienating staff members with his loud and aggressive questions about his grandchild's care. The nurse's best action in this case is to

- A. politely ask the grandfather not to ask so many questions.
- B. formulate a plan with the grandfather to get his questions answered in a way that respects the medical staff.
- C. deflect the grandfather's questions to another member of the medical team.
- D. ask that nurses be rotated to minimize the stress of dealing with a difficult family member.

Answer: B

Explanation:

Dealing with hostile or "difficult" family members is one of the most challenging aspects of pediatric nursing care and requires a great deal of patience, compassion, and resilience. Deflection and avoidance are tempting but are not the best practice for the nurse, fellow staff, the patient, or the difficult family member. Ongoing disrespectful treatment of the medical team is not acceptable and impairs patient care and adequate communication with the patient's caregivers. Ideally, the critical care nurse draws upon his or her conflict resolution resources to maintain respectful and honest communication with the family, while assisting the family in getting their needs met in a more appropriate way.

Question: 16

A patient has been in the ICU for 2 weeks for the treatment of intracerebral hemorrhage, seizures, and hospital-acquired pneumonia

- a. Which one of the following should be included in the patient's plan of care to prevent post-intensive care syndrome (PICS)?
- A. Maintain bed rest to prevent injury.
 - B. Use benzodiazepines for sedation.
 - C. Reduce the brightness of the room lighting, and reduce patient stimulation at night to promote sleep.
 - D. Bypass daily spontaneous breathing trials to allow for pulmonary rest.

Answer: C

Explanation:

Post-intensive care syndrome (PICS) is a collection of psychological and/or physical sequelae in patients and families After ICU discharge. Delirium can contribute to long-term psychological effects resulting from ICU admissions. Allowing for adequate rest and keeping the patient oriented to time (day versus night) prevents ICU delirium. Early mobility reduces the risk for long-term physical disability associated with PICS. The use of benzodiazepines for sedation increases the patient's risk for delirium. Daily spontaneous breathing trials should not be avoided because they reduce the risk for delirium, as well as contribute to earlier extubation, which can prevent the risk of long-term respiratory complications related to PICS.

Question: 17

A 15-year-old patient in the ICU has been admitted for pulmonary edema and respiratory distress. The patient has a history of leukemia and received her last chemotherapy treatment 5 days ago, The patient's lab results are as follows:

White blood cell count: 2.1 thousand per μL

Red blood cell count: 3.5 million per μL

Hemoglobin 10 g/dL

Hematocrit: 31%

Platelets: 180 thousand per μL

Absolute neutrophil count: 0.042 thousand per μL

Which one of the following interventions should the nurse include in the patient's plan of care?

- A. Maintain a current blood type and match at all times in anticipation of a stat transfusion.
- B. Have all staff and visitors wash their hands and wear a mask.
- C. Avoid aspirin and NSAIDs.
- D. Add raw fruits and vegetables to this patient's meal trays.

Answer: B

Explanation:

An absolute neutrophil count of <0.5 thousand per VIL indicates severe neutropenia. All visitors and staff should wash their hands and wear a mask before coming into contact with the patient to prevent infection. The patient's hemoglobin and hematocrit levels are low but not critical and do not require treatment with a stat transfusion at this time. The patient's platelet count is within normal limits and does not require bleeding/thrombocytopenia precautions to include the avoidance of aspirin and NSAIDs. Raw fruits and vegetables can carry foodborne bacteria and may lead to infection in the patient.

Question: 18

A 7-month-old boy with unrepaired tetralogy of Fallot is in the intensive care unit with an accidental partial-thickness scald burn. Due to an error, he does not receive two scheduled doses of pain medication and is crying uncontrollably because of the pain. The critical care nurse notes that he suddenly develops worsening agitation, cyanosis, and tachypnea

a. His usual prominent

murmur is no longer audible on auscultation, In this situation, the nurse expects that the initial treatment is most likely to be

- A. nebulized albuterol administration.
- B. placement of the infant in the knee—chest position to increase systemic vascular resistance.
- C. emergent needle decompression of a probable tension pneumothorax.
- D. transthoracic cardiac pacing.

Answer: B

Explanation:

Tetralogy of Fallot is characterized by ventricular septal defect, pulmonic stenosis, overriding aorta, and right ventricular hypertrophy. This patient's rapid change in status is consistent with a "Tet spell" or a hypercyanotic episode. Tet spells may occur spontaneously or in association with agitation, hypotension, or crying. The inciting event of a Tet spell is worsening of the right ventricular outflow tract obstruction, which causes increased right-to-left shunting through the ventricular septal defect. This leads to decreased pulmonary blood flow and hypoxia, which increases pulmonary vascular resistance, creating a cycle of worsening hypoxia and impaired pulmonary blood flow. During an acute Tet spell, the patient's usual pulmonic stenosis murmur is absent or markedly decreased. Treatment is aimed at decreasing systemic venous return and increasing systemic vascular resistance (to reverse the right-to-left shunting). This is accomplished by placing the child in the knee—chest position and attempting to calm the child. If this fails to abort the hypercyanotic episode, oxygen, intravenous fluids, morphine, phenylephrine, or sedation may be required. If persistent, a Tet spell may progress to syncope, seizure, cerebrovascular accident, or death.

Question: 19

The critical care nurse is taking care of a 4-year-old child who is being treated for bacterial meningitis. Laboratory assessment reveals hyponatremia (serum sodium = 122 mEq/L), decreased serum osmolality, and elevated urine osmolality, consistent with a diagnosis of syndrome of inappropriate antidiuretic hormone secretion. The critical care nurse expects the primary treatment measure to be

- A. rapid correction of hyponatremia.
- B. fluid restriction.
- C. vasopressin administration.
- D. restriction of glucose administration.

Answer: B

Explanation:

The primary derangement in syndrome of antidiuretic hormone (SIADH) is inappropriate elevation of antidiuretic hormone (vasopressin) levels in the setting of euolemia, leading to increased free water absorption in the kidneys and a dilutional hyponatremia. Serum osmolality is low, urine is inappropriately concentrated, and urine sodium excretion is elevated. Clinically, the patient's symptoms reflect the degree and acuity of hyponatremia and may include nausea, vomiting, headache, mental status changes, and seizures. The primary treatment of SIADH is fluid restriction, which leads to elimination of excessive fluid volume and a decrease in urine sodium excretion. Rapid correction of hyponatremia should be avoided due to the risk of

central pontine myelinolysis. Hypertonic saline Administration is generally indicated only in the setting of severe neurologic symptoms and should only be used for partial correction of hyponatremia. Vasopressin administration would exacerbate the problem in a patient with SADH.

Question: 20

A 16-year-old patient in the critical care unit has an external ventriculostomy placed for acute hydrocephalus secondary to a brain tumor. Over the course of a 4-hour period, he becomes progressively more lethargic and complains of severe headache despite pain medication; the nurse notes that his pupils are symmetric in size but sluggishly reactive. The nurse finds the bedside ventriculostomy drainage bag unexpectedly full. On the basis of this information, the critical care nurse suspects that the most likely explanation for the patient's deterioration is

- A. ventriculostomy catheter-related meningitis.
- B. clogging of the ventriculostomy catheter leading to inadequate cerebrospinal fluid drainage.
- C. excessive drainage of cerebrospinal fluid by the ventriculostomy drain.
- D. progression in size of the patient's brain tumor.

Answer: C

Explanation:

Ventriculostomy devices allow for continuous intracranial pressure (ICP) monitoring and cerebrospinal fluid (CSF) drainage to an external collection device. They are less commonly used for the administration of medications or dye. The ventriculostomy catheter is placed in one of the patient's lateral ventricles and then connected externally to a collection bag. The position of the collection bag relative to the patient's head determines the rate of CSF drainage. Monitoring the patient's scalp incision, the amount and color of CSF drainage, and careful attention to the proper positioning of the collection device are paramount to preventing ventriculostomy-related complications. Over drainage or under drainage of CSF can lead to tentorial herniation. The description of a drainage bag that is unexpectedly full in this case suggests excessive CSF drainage. Infection is not uncommon in patients with ventriculostomy catheters. Although catheter-related meningitis may present similarly to impending herniation, CSF volume would not normally be increased.

Question: 21

A 2-week-old previously healthy infant presents to the emergency department with vomiting and lethargy. The parents report that the infant was well until 3 hours before, when he refused his usual feeding and was more fussy than usual. Soon after, he had several episodes of forceful bilious emesis and has been lethargic since then. Initial vital signs show a temperature of 37 °C, a heart rate of 190 beats/min, a respiratory rate of 60 breaths/min, blood pressure of 80/45 mmHg, and an oxygen saturation of 97% on room air. The infant is noted to be listless and poorly perfused with adequate respiratory effort. Abdominal examination reveals a mildly distended abdomen with decreased bowel sounds and diffuse tenderness. Which of the following interventions is most appropriate at this time?

- A. Prepare the infant for transport to abdominal ultrasound to evaluate for hypertrophic pyloric stenosis.
- B. Place the infant on supplemental oxygen, and gather supplies for intubation.

- C. Prepare to place a nasogastric tube. and obtain vascular access for fluid resuscitation.
- D. Begin oral rehydration therapy with an appropriate electrolyte solution. such as Pedialyte.

Answer: C

Explanation:

Bilious vomiting in infancy is presumed to represent an intestinal obstruction until proven otherwise. History and physical examination in this case are consistent with an intra-abdominal emergency. The patient described in the question has adequate respiratory effort with normal oxygen saturation and does not require further respiratory support at this point. The likely diagnosis in this case is midgut volvulus secondary to malrotation. Typically, these infants present in the first few weeks of life with bilious vomiting. Once bowel ischemia develops, there is generally rapid decompensation to shock and metabolic acidosis. Initial management consists of nasogastric tube placement for bowel decompression, intravenous fluid resuscitation, and emergent surgical evaluation. Imaging, such as abdominal x-rays, an upper gastrointestinal series, and ultrasound are indicated only if the patient is stable. Given the concern for intestinal obstruction, the infant should not be fed. Hypertrophic pyloric stenosis presents in the first 3–6 weeks of life with nonbilious projectile vomiting after feeding. The infant generally appears well and feeds eagerly until there is moderate dehydration secondary to the intractable vomiting. The abdomen is not typically tender. The hypertrophic pylorus may be palpable.

Question: 22

All of the following lab findings are consistent with acute kidney injury EXCEPT

- A. metabolic alkalosis.
- B. elevated blood urea nitrogen.
- C. elevated serum phosphorus.
- D. elevated serum potassium.

Answer: A

Explanation:

Acute kidney injury leads to a variety of metabolic derangements beyond the expected elevation in blood urea nitrogen and serum creatinine. Microscopic urinary examination is generally normal in prerenal and postrenal failure but may reveal protein, blood, or casts with intrarenal failure. Typically, patients with acute kidney injury demonstrate metabolic acidosis from impaired hydrogen ion excretion and bicarbonate reabsorption, hyperkalemia from impaired renal potassium excretion, hyperphosphatemia from impaired phosphate excretion, hypocalcemia from decreased renal calcitriol production. and normocytic anemia from impaired erythropoietin production. Treatment is aimed at identifying and treating the underlying cause of acute kidney injury and managing the metabolic abnormalities acutely.

Question: 23

The critical care nurse is taking care of a 16-year-old patient with chronic medical problems who is in her first trimester of an unintended pregnancy. After multiple discussions with the care team, including the risks and benefits of this course of action, the patient has decided to undergo

a therapeutic abortion. Her family is supportive of this decision. The personal opinion of the nurse is that therapeutic abortion is morally wrong, and she is extremely uncomfortable with the patient's decision. The most appropriate plan of action for this nurse is to

- A. support the right of the patient and family to make their own decisions but request professional support.
- B. bring additional information to the patient highlighting the moral arguments against elective therapeutic abortion.
- C. refuse to participate in this patient's care without giving an explanation.
- D. ask the hospital chaplain to convince the patient to change her mind.

Answer: A

Explanation:

Often, the nurse's advocacy and moral agency obligations do not create conflict with the nurse's personal beliefs, but there will definitely be times in one's career when the personal wishes of the patients and their families are in conflict with the nurse's personal ethical principles. It is at these times that it is particularly crucial for the nurse to obtain the support he or she needs to continue fulfilling his or her obligation to assist the patient and family in making informed decisions, which reflect their beliefs and values. Bringing one-sided information, advocating for a particular course of action, and enlisting another staff member in an attempt to influence the decisions of patients and their families are inappropriate.

Question: 24

A 15-year-old girl who was treated for Guillain-Barré syndrome develops progressive shortness of breath. Bedside forced vital capacity (FVC) reveals a FVC of 8 mL/kg (normal = 15–20 mL/kg) and a maximum inspiratory pressure of 18 cm H₂O (normal > 30 cm H₂O). In this clinical scenario, which of the following interventions is most appropriate?

- A. Transcutaneous cardiac pacing
- B. Nebulized bronchodilator administration
- C. Intramuscular epinephrine administration
- D. Endotracheal intubation

Answer: D

Explanation:

Guillain-Barré syndrome is typically a progressive, ascending demyelinating neuropathy characterized by loss of deep tendon reflexes and weakness. Sensory changes, autonomic system involvement, and cranial nerve involvement may also be present. Up to one-third of patients with Guillain-Barré syndrome require mechanical ventilation due to respiratory failure caused by diaphragmatic weakness. Bedside forced vital capacity (FVC) and peak inspiratory pressure (PIP) may be measured serially to detect declining respiratory status. Patients with worsening FVC/PIP measurements or hypoxemia in the setting of Guillain-Barré require intubation until they have improved. Cardiac pacing may be indicated in the patient with heart block or symptomatic bradycardia as a result of autonomic nervous system involvement, but this patient's respiratory failure is due to muscle weakness and would, therefore, not be improved by cardiac pacing. Neither epinephrine nor bronchodilators will likely improve this patient's respiratory deterioration.

Question: 25

A 4-month-old infant is hospitalized with respiratory syncytial virus bronchiolitis. Assessment reveals an alert, fussy infant with coarse breath sounds, moderate retractions, and expiratory grunting. Respiratory rate is 68 breaths/min, and oxygen saturation is 95% with supplemental oxygen by nasal cannula.

a. Arterial blood gas measurements reveal the following:

pH: 7.30
PCO₂: 50 mmHg
PO₂: 130 mmHg
HCO₃: 24 mEq/L

Appropriate management of this patient consists of

- A. a trial off supplemental oxygen.
- B. breastfeeding ad lib.
- C. nebulized budesonide administration.
- D. nasal continuous positive airway pressure trial.

Answer: D

Explanation:

Bronchiolitis is an infectious illness characterized by small airway collapse and production of mucus, which usually begins with 1–2 days of nasal congestion and mild cough (+/- fever). Several days into the illness, the patient develops worsening cough and increased work of breathing, often accompanied by poor feeding, wheezing, and irritability. Young or premature infants may have a significant degree of apnea. Respiratory syncytial virus is the most common viral etiologic agent.

The patient described in the question is alert and adequately oxygenated but is showing signs of moderate respiratory distress: arterial blood gases reveal a mild uncompensated respiratory acidosis. A trial of nasal continuous positive air pressure would be reasonable given this patient's respiratory status. Continuous positive air pressure increases functional residual capacity by increasing the mean airway pressure, resulting in decreased airway resistance and improved ventilation/perfusion matching. Clinically, this often leads to improved ventilation and oxygenation. Oral feedings should be withheld in this infant until the respiratory status improves. It would be inappropriate to remove the supplemental oxygen from this patient. Nebulized steroids have not been shown to be beneficial in the setting of acute bronchiolitis.

Question: 26

Which of the following statements regarding the use of sedation and analgesia in the pediatric critical care unit is most accurate?

- A. Sedatives that produce prolonged sedation after the medication is discontinued are ideal in the critical care setting
- B. Adequate sedation and analgesia of the critical care patient decreases the patient's physiologic stress response
- C. Continuous monitoring of the critical care patient's response to analgesic and sedative medications is generally performed by the physician
- D. Sedation generally makes it more difficult for the critical care patient to tolerate mechanical Ventilation

Answer: B

Explanation:

Optimal sedation and analgesia in the critical care patient depend on the patient's underlying medical condition as well as the therapeutic and side effect profile of the medications being used. The physiologic stress response to serious illness and typical intensive care unit care (e.g., central line placement, mechanical ventilation) increases metabolic demand and can interfere with patient recovery. Ideally, the use of sedatives and analgesics in the critical care unit allows for patient comfort during painful procedures or medical conditions and a decreased stress response as well as avoidance of complications of analgesic/sedative administration. The patient's response to sedatives and analgesics is monitored primarily by the critical care nurse.

Question: 27

The critical care nurse is taking care of a patient with chronic thrombocytopenia who has just undergone a percutaneous renal biopsy. Which of the following biopsy-related complications is most likely in this patient?

- A. Urinary retention
- B. Excessive bleeding
- C. Excessive post-biopsy pain
- D. Infection

Answer: B

Explanation:

The most common complication after percutaneous renal biopsy is excessive bleeding. The patient described in the question is at increased risk for bleeding after renal biopsy as a result of underlying chronic thrombocytopenia. Although most patients have some pain after renal biopsy, it generally resolves after several hours: this patient has no underlying problems that would lead one to think he or she would have excessive post-biopsy pain. Infection is rare after renal biopsy with sterile technique and routine wound care. Urinary retention is not usually associated with renal biopsy. A more serious complication after renal biopsy is the formation of an arteriovenous fistula, which may resolve without intervention.

Question: 28

A 14-year-old girl with a known peanut allergy is admitted to the critical care unit after accidentally ingesting food containing peanut oil. She was treated before arrival with intramuscular epinephrine, intravenous fluids, and intravenous corticosteroids. On arrival, she is alert and in no distress. Three hours later, the patient becomes very anxious and develops wheezing, vomiting, tachycardia, and diffuse urticaria.

- a. The most likely explanation for this patient's clinical course is
- A. an allergic reaction to one of the medications she received in the hospital.
 - B. late phase anaphylaxis from the initial peanut oil ingestion.
 - C. new peanut ingestion or exposure while in the critical care unit.

D. epinephrine toxicity.

Answer: B

Explanation:

Anaphylaxis is a severe, systemic allergic reaction that presents with a variety of symptoms, including urticaria, stridor, wheezing, syncope, vomiting, diarrhea, and cardiovascular or respiratory arrest. Initial symptoms generally begin within minutes of exposure to the allergen. Up to 20% of patients with anaphylaxis will have a biphasic reaction, characterized by a return of anaphylaxis symptoms several hours after initial treatment and improvement. The time period between the two phases of anaphylaxis may be up to 36 hours in some patients. Secondary reactions can be more or less severe than the initial phase of anaphylaxis. Corticosteroid administration in the initial phase of anaphylaxis appears to prevent or decrease the severity of late anaphylactic reactions. Management is the same with early and late-phase anaphylaxis. The mainstay of treatment is intramuscular or intravenous epinephrine administration. Supportive therapies include nebulized racemic epinephrine or beta agonists, corticosteroids, antihistamines (H1 and H2 blockers), and intravenous fluid administration.

Question: 29

In which of the following congenital heart defects would systemic-to-pulmonary-artery palliative shunting (e.g., Blalock-Taussig shunt) most likely be indicated?

- A. Total anomalous pulmonary venous return
- B. Tricuspid atresia
- C. Isolated ventricular septal defect
- D. Transposition of the great arteries

Answer: B

Explanation:

Palliative shunting from the systemic to pulmonary circulation increases pulmonary blood flow in the patient with congenital heart disease characterized by impaired pulmonary circulation pending definitive repair. Congenital heart defects that may benefit from palliative shunting are those in which pulmonary circulation is inadequate as a result of pulmonary outflow atresia or obstruction or in which systemic blood flow is dependent on pulmonary circulation. Examples include hypoplastic left heart syndrome, tetralogy of Fallot (pulmonic stenosis), tricuspid atresia, and pulmonary atresia without an interventricular shunt. Total anomalous pulmonary venous return is characterized by excessive pulmonary blood flow therefore, systemic-to-pulmonary shunting would exacerbate the problem. Transposition of the great arteries results in parallel systemic and pulmonary circulations in which oxygenated blood is returned to the right heart and desaturated blood is pumped to the systemic circulation. Communication between the two circulations is required (by patent ductus arteriosus, ventricular septal defect, or atrial septal defect) to provide adequate oxygenation to body tissues, pending surgical repair. Increasing pulmonary blood flow by palliative shunting is not indicated in these patients. Large isolated ventricular septal defects result in excessive pulmonary blood flow, and therefore, a procedure increasing pulmonary blood flow would be counterproductive.

Question: 30

A critical care nurse is taking care of a 16-year-old poorly compliant patient with insulin-dependent diabetes mellitus who presents with vomiting and dehydration. Physical examination reveals an appropriately responsive young woman who appears tired with Kussmaul respirations and poor peripheral perfusion. Bedside serum glucose is 580 mg/dL. An initial arterial blood gas reveals the following:

pH: 7.03
PCO₂: 16 mmHg
PO₂: 130 mmHg
HCO₃: 5 mEq/L

In this clinical scenario, the critical care nurse expects the initial treatment to include

- A. intravenous mannitol.
- B. continuous intravenous insulin administration.
- C. intravenous broad-spectrum antibiotics.
- D. subcutaneous insulin administration.

Answer: B

Explanation:

The patient described in the question has insulin-dependent diabetes mellitus and has not been compliant with exogenous insulin administration. Insulin noncompliance leads to hyperglycemia and dehydration secondary to the resultant osmotic diuresis. Glucose-starved cells use ketone bodies as an alternative fuel source, and excessive ketoacid production leads to diabetic ketoacidosis (DKA). This patient has DKA and is dehydrated. Mannitol administration is not indicated in the patient with normal mental status and no signs of increased intracranial pressure. Although many episodes of DKA are triggered by infection, antibiotics would not be included in the immediate stabilization of this patient. Subcutaneous insulin administration is appropriate once the patient with DKA is tolerating oral intake and is no longer acidotic. In the significantly acidotic and dehydrated patient (as in this case), it is preferable to administer continuous insulin intravenously, allowing for careful titration of fluid and insulin administration.

Question: 31

A 5-year-old previously healthy boy is admitted to the intensive care unit with a 12-hour history of fever, severe headache, and vomiting. Physical examination reveals a febrile, lethargic child with tachycardia, neck stiffness, and poor peripheral perfusion. Soon after arrival in the intensive care unit, he develops a purple non-blanching rash on his lower extremities. The most likely etiology for his illness is

- A. Henoch-Schönlein purpura.
- B. Streptococcus pneumoniae.
- C. acute lymphocytic leukemia.
- D. Neisseria meningitidis.

Answer: B

Explanation:

The development of a petechial or purpuric rash in the setting of a febrile illness is concerning for meningococcal disease. Acute infection caused by *Neisseria meningitidis* (a gram-negative encapsulated diplococcus) generally progresses rapidly and is characterized by either meningitis, septicemia, or a combination of both. Treatment consists of fluid resuscitation, prompt antibiotic administration, blood pressure support as indicated, and close hemodynamic, respiratory, and neurologic monitoring. Henoch-Schönlein purpura (HSP) is a systemic vasculitis characterized by arthritis, extremity edema, abdominal pain, and a purpuric rash, which is classically present from the waist down. Meningitis and rapid clinical deterioration are not associated with HSP. Although *Streptococcus pneumoniae* can cause critical illness with a petechial or purpuric rash, the clinical scenario in this case is more often associated with *N. meningitidis*. Patients with acute lymphocytic leukemia are at increased risk for invasive, severe, infectious illness and can have petechial rashes secondary to thrombocytopenia. Given the clinical scenario in this case, meningococcal disease is the most likely explanation.

Question: 32

A critical care nurse is taking care of a child who is initiating enteral feeds through a recently placed percutaneous endoscopic gastrostomy tube. This patient's plan of care should include which of the following protocols?

- A. The feeding rate is gradually advanced while assessing the patient for symptoms of feeding intolerance.
- B. Medications are administered through the feeding tube by dissolving them in the hanging bag of formula.
- C. Enteral feedings are initiated at full strength and volume to maintain patency of the feeding tube.
- D. The insertion site should be left alone and not cleaned for 48 hours.

Answer: A

Explanation:

Care of the recently placed enteral feeding tube includes monitoring for wound irritation/infection, assessing patient tolerance of enteral feedings, and avoiding clogging of the tube. The feeding tube insertion site should be inspected and gently cleaned daily. If there is an external plastic component to the feeding tube, it should be rotated daily to avoid skin breakdown and irritation due to pressure from the device. Feedings should be started gradually with any new enteral tube and then increased systematically to the goal volume and rate, making sure to assess the patient for symptoms of feeding intolerance (e.g., pain, vomiting, increasing abdominal girth). Medications should be dissolved as much as possible before administration through the feeding tube, and the tube should be flushed thoroughly before and after medication administration to avoid clogging. Medication should not be dissolved in a large-volume bag of formula due to the frequent incidence of precipitation of medications over time.

Question: 33

A critical care nurse notes that many patients being treated with chronic narcotics are developing symptomatic constipation due to a lack of consistent inclusion of stool softener in the medication regimen. In this case, the nurse's best practice is to

- A. collaborate in the development of a standardized treatment plan for the prevention of constipation in patients on chronic narcotic therapy.
- B. ask the physician to order stool softeners for the patients on chronic narcotic therapy.
- C. shift his or her focus to medical issues more relevant to critical care practices.
- D. minimize narcotic administration (e.g., giving fewer "as needed" doses) to the patients needing this therapy.

Answer: A

Explanation:

Although individual attention to one's own practice is important and often effective in minimizing the risk of adverse outcomes for the patient, it is also important to identify challenges that apply to patients or staff in general to optimize patient care and safety. Ideally, problems are identified before a serious event occurs, allowing for staff to enhance their professional knowledge and collaborate in establishing evidence-based care plans that improve patient comfort and safety. Although the clinical concern in this case may seem minor relative to other critical care issues, patient comfort is an important consideration in the critical care unit. Intentionally under treating pain in the pediatric patient to avoid narcotic-associated constipation is not appropriate.

Question: 34

All of the following conditions are associated with an increased risk of aspiration pneumonia EXCEPT

- A. a depressed level of consciousness secondary to drug overdose.
- B. bacterial cervical lymphadenitis.
- C. a tracheoesophageal fistula.
- D. traumatic brain injury.

Answer: B

Explanation:

Aspiration pneumonia is generally caused by aspiration of gastric contents or oral-pharyngeal organisms. Acute or chronic underlying conditions, leading to a disruption in the patient's ability to protect the upper airway, or anatomic or mechanical factors, interfering with the patient's usual airway protective reflexes, are associated with an increased risk of pulmonary aspiration and subsequent infectious pneumonia. Conditions that impair a patient's level of consciousness, such as a drug overdose, brain injury, seizures, critical illness, and sedation or anesthesia all increase the patient's risk of aspiration. Neuromuscular disorders that lead to decreased coordination in swallowing, such as myasthenia gravis or hypoxic-ischemic encephalopathy, also increase aspiration risk. Gastrointestinal dysfunction or anatomic abnormalities of the upper airway or gastrointestinal tract, such as tracheoesophageal fistula, severe gastroesophageal reflux disease, or nasogastric feeding tubes, increase the risk of aspiration as well. Bacterial cervical lymphadenitis is not likely to increase the risk of aspiration pneumonia.

Question: 35

A 10-year-old boy with sickle cell disease is admitted for treatment of a vaso-occlusive pain crisis involving his lower extremities. During his hospitalization, he develops fever, hypoxia, and

respiratory distress. Chest x-ray demonstrates a new upper lobe infiltrate. On the basis of this information, the nurse suspects that the patient has developed

- A. influenza.
- B. acute chest syndrome.
- C. atelectasis.
- D. hypoventilation secondary to narcotic administration.

Answer: B

Explanation:

Acute chest syndrome is a common complication of sickle cell disease in many pediatric patients and is often recurrent. Acute chest syndrome is generally defined as a new infiltrate on chest x-ray in association with fever, cough, hypoxia, or shortness of breath in a patient with sickle cell disease. Patients may present with acute chest syndrome initially or may develop it in association with other conditions, such as acute infection or non-chest-related vaso-occlusive pain crisis. Treatment is generally supportive with pain control, incentive spirometry, supplemental oxygen, bronchodilators, and careful fluid management. Exchange transfusions are indicated for clinical deterioration despite maximal supportive care. Respiratory depression is common in association with narcotic administration in the sickle cell patient but is not associated with fever, respiratory distress or an infiltrate on x-ray. Influenza may cause all of the symptoms in this patient and testing and treatment should be considered in the appropriate clinical situation, but acute chest syndrome should be assumed until proven otherwise.

Question: 36

A 16-year-old girl is admitted to the critical care unit after an intentional ingestion of an unknown amount of amitriptyline (tricyclic antidepressant). Assessment reveals a disoriented girl with tachycardia, dilated pupils, and adequate respiratory effort. Electrocardiogram reveals sinus tachycardia with a QRS interval of 160 milliseconds (normal < 110 msec). Given this information, the critical care nurse anticipates which of the following interventions?

pH: 7.26
PCO₂: 51 mmHg
PO₂: 110 mmHg
HCO₃: 24 mEq/L

- A. Intravenous sodium bicarbonate administration
- B. Emergent hemodialysis
- C. Intravenous benzodiazepine administration
- D. Continued monitoring until symptoms resolve

Answer: A

Explanation:

Tricyclic antidepressants (TCAs) are easily absorbed from the gastrointestinal tract and distribute widely in tissue, often at significantly higher levels in the brain and cardiac tissue than in plasma. Toxic effects are due to anticholinergic effect (e.g., dry mouth/skin, pupillary dilation, tachycardia, altered mental status,

seizure). Alpha blockade. and direct myocardial toxicity (e.g., vasodilation, hypotension, impaired cardiac conduction). Symptoms of overdose are apparent within 1—2 hours of ingestion, and the most serious complications occur within 6—8 hours of ingestion. The most important diagnostic study with a TCA overdose is the 12-lead electrocardiogram (EKG). The EKG findings include sinus tachycardia, prolonged PR/QRS/QTc intervals, and ST-T wave changes. A QRS duration over 100 msec is associated with increased risk of seizures and life-threatening cardiac arrhythmia with a proportionally increased risk as the QRS duration increases. Treatment includes airway/circulatory supportive care in addition to gastric decontamination with activated charcoal or gastric lavage. Sodium bicarbonate administration is indicated for a QRS duration over 100 msec or cardiac dysrhythmia. Sodium bicarbonate with a TCA overdose leads to uncoupling of TCA from myocardial sodium channels. A TCA overdose is not responsive to hemodialysis.

Question: 37

A 12-year-old boy is slowly recovering from a serious motor vehicle accident during which he suffered an upper thoracic spinal cord injury. During one of his physical therapy sessions, his left patella is momentarily dislocated but quickly returns to its normal position. Immediately afterward, the patient acutely complains of headache and blurry vision and appears very anxious. Vital signs reveal blood pressure of 170/100 mmHg and a heart rate of 54 beats/min. Physical examination demonstrates an anxious patient who has flushed skin and diaphoresis, involving his face, neck, and shoulders. The most likely explanation for this clinical scenario is

- A. acute fat embolus secondary to his knee injury.
- B. autonomic dysreflexia secondary to his spinal cord injury.
- C. pheochromocytoma.
- D. anxiety.

Answer: B

Explanation:

Autonomic dysreflexia episodes occur in patients with spinal cord injuries above the midthoracic region and are potentially devastating as a result of complications of acute severe hypertension if episodes are not managed aggressively. Autonomic dysreflexia episodes are usually triggered by an uncomfortable sensation marked sympathetic nervous system reaction is triggered, leading to vasoconstriction. The brain attempts to moderate the sympathetic nervous system response via inhibitory pathways and activation of the parasympathetic nervous system, but these impulses are blocked at the level of the spinal cord injury. Thus, the sympathetic nervous system reaction prevails below the level of the injury, and the parasympathetic nervous system reaction is dominant above the level of the injury. This leads to marked systemic hypertension, bradycardia, flushing, and sweating above the level of the spinal cord injury, pounding headache, and nasal congestion. Management consists of identification and removal of the inciting stimulus (e.g., blocked urinary catheter, pressure sore, constipation, ingrown toenail) and emergent hypertension management.

Question: 38

A critical care nurse is taking care of a 4-year-old boy who was involved in a serious motor vehicle collision and suffered significant blunt abdominal injury. Surgical evaluation and imaging reveal no injuries that require operative exploration, and the child is admitted to the critical care

unit after intubation and aggressive fluid resuscitation. Within hours, the patient's clinical condition worsens considerably. Pulmonary compliance and urine output are markedly decreased. The abdomen is tense and significantly more distended than on admission. Central venous pressure is elevated despite signs of decreased cardiac output. Re-evaluation rules out intra-abdominal hemorrhage, perforation, or rupture. Based on this information, the critical care nurse suspects which of the following complications?

- A. Displacement of the endotracheal tube
- B. Abdominal compartment syndrome
- C. Pulmonary embolus
- D. Unrecognized pelvic fracture

Answer: B

Explanation:

Compartment syndrome is traditionally associated with extremity fractures but may occur in any closed body cavity, including the abdomen. Abdominal compartment syndrome is characterized by impaired perfusion to the abdominal organs secondary to interstitial edema, capillary leak, and decreased compliance of the abdominal wall. It may occur with a primary abdominal insult (e.g., blunt trauma, pancreatitis, peritonitis) or may occur secondary to serious systemic illness (e.g., sepsis, burns). Effects of elevated intra-abdominal pressure lead to multisystem manifestations. Pulmonary compliance is decreased due to mechanical restrictive effects of elevated pressure in the abdominal cavity. Cardiac output is decreased and systemic vascular resistance is increased as the systemic circulation attempts to perfuse in the setting of elevated abdominal pressure. Oliguria may develop as renal perfusion is decreased secondary to increased abdominal pressure and decreased overall cardiac output. Decreased perfusion of abdominal organs leads to bowel ischemia and increased risk of perforation and peritonitis. Increasing abdominal girth or distention in the presence of the above manifestations should prompt consideration of abdominal compartment syndrome.

Question: 39

A critically ill adolescent patient is being treated for agitation and delirium with haloperidol. Which of the following side effects or toxicities are most likely to be associated with haloperidol administration?

- A. Acute dystonic reaction
- B. Polycythemia
- C. Hypothermia
- D. QT-interval shortening

Answer: A

Explanation:

Haloperidol is an antipsychotic medication used in the treatment of acute and chronic psychosis, Tourette syndrome, and agitation. It is generally administered intramuscularly or orally. Intravenous administration is associated with an increased incidence of cardiac arrhythmia secondary to QT prolongation when compared to oral or intramuscular administration. Haloperidol is associated with a number of

potentially serious side effects. Neurologic side effects include parkinsonian-like symptoms, tardive dyskinesia, and acute dystonic reactions. Haloperidol also causes QT prolongation and an increased risk of torsades de pointes ventricular tachycardia. Neuroleptic malignant syndrome (i.e., hyperpyrexia, muscle rigidity, rhabdomyolysis) may occur with haloperidol administration.

Question: 40

The critical care nurse is caring for a patient who is critically ill after a motor vehicle accident and requires daily dressing changes of her abdominal wounds. The patient's parents ask if they can participate in the dressing changes so that they can "help her get better." Which of the following responses by the critical care nurse is most appropriate?

- A. Remind the parents that someone will teach them to change her dressings once the patient is getting ready for discharge.
- B. Inform the parents that changing her wound dressings does not contribute very much to her "getting better."
- C. Remind the parents that only people with medical training should be handling their daughter's dressings.
- D. Assist in teaching the parents how to do the dressing changes and encourage them to participate daily.

Answer: D

Explanation:

Early involvement of family members in routine patient care in the critical care unit can help significantly with minimizing the feelings of helplessness and powerlessness that often accompany a child's serious injury or diagnosis. In addition to assisting the caregivers to feel empowered in caring for their family member, it may also be particularly healing for the patient when family members are able to participate in their care. Minimizing the family's sense of their contribution to the child's recovery or dismissing their interest is neither appropriate nor compassionate.

Question: 41

In which of the following clinical scenarios is continuous intracranial pressure monitoring most appropriate?

- A. A 12-year-old boy with moderately severe headache and Glasgow Coma Scale (GCS) score of 15 after sustaining a head injury during a fall from his bicycle
- B. A 2-year-old girl with vomiting and GCS score of 7 after striking the right side of her head falling from her father's shoulders
- C. A 5-year-old girl with a ventriculoperitoneal shunt for congenital hydrocephalus who is admitted for acute appendicitis
- D. A 10-year-old boy at his neurologic baseline with poorly controlled epilepsy admitted for increased seizures

Answer: B

Explanation:

Treatment of traumatic brain injury begins with the usual assessment and management priorities: managing airway and ventilation while protecting the cervical spine and supporting intravascular volume. Recognition and management of elevated intracranial pressure (ICP) should begin as soon as possible after

attention to the patient's airway, breathing, and circulation. Elevation of the head to 30 degrees, aggressive management of hypotension and hypoxemia, intravenous mannitol, mild hyperventilation, and the use of neuroprotective agents to avoid spikes in ICP during intubation will likely be required in the patient with severe traumatic brain injury. Continuous intracranial pressure monitoring allows for early recognition of worsening intracranial hypertension and enhances the ability of the critical care team to optimize cerebral perfusion with ICP-lowering interventions and careful management of the patient's hemodynamic status. Continuous monitoring also allows for assessment of the patient's ICP response to medical interventions. Types of intracranial pressure monitors include ventricular, intraparenchymal, epidural, subdural, and subarachnoid (bolt) devices. Patients with reassuring neurologic examinations or at their baseline neurologic status do not require continuous intracranial monitoring.

Question: 42

A pediatric patient is intubated and placed on a volume-cycled mode of mechanical ventilation. Arterial blood gas reveals the following:

Which of the following ventilator adjustments would most likely improve this patient's acid—base status?

- A. Increase fraction of inspired oxygen
- B. Decrease the mandatory respiratory rate
- C. Increase the set tidal volume/breath
- D. Increase the set inspiratory time

Answer: C

Explanation:

The arterial blood gas of the patient described in the question reveals acute respiratory acidosis without renal compensation, decreased arterial pH in the setting of elevated PCO_2 and normal serum bicarbonate. Different modes of mechanical ventilation are used, depending on each patient's specific pulmonary mechanics and ventilatory requirements. In this case, the patient is ventilated with a volume-cycled mode, in which a set tidal volume is delivered to the patient with each ventilator-administered breath, and the airway pressure varies, depending on the patient's pulmonary compliance. To improve this patient's acid—base status, using the ventilator (rather than metabolic compensation), this patient's respiratory acidosis (hypercapnia) needs to be corrected. An increase in minute ventilation will result in decreased $PACO_2$ and improved arterial pH. Minute ventilation is defined as tidal volume \times respiratory rate; therefore, either an increase in respiratory rate or tidal volume should correct this patient's acidosis. Increasing either the fraction of inspired oxygen or inspiratory time will primarily improve the patient's oxygenation, rather than ventilation.

Question: 43

A 12-year-old boy with anaphylactic shock has a catheter placed for monitoring central (CVP). Which of the following statements is most accurate regarding CVP venous pressure monitoring in the critically ill patient?

- A. The CVP is a reflection of right atrial pressure and systemic venous return.
- B. Cardiac failure usually results in decreased CVP.
- C. Monitoring CVP is not helpful if large shifts in fluid status are anticipated.
- D. Hypovolemia is reflected in an elevated CVP.

Answer: A

Explanation:

Central venous pressure (CVP) monitoring is generally indicated in the patient who requires close intravascular volume status monitoring, frequent venous blood sampling, or infusion of vasoactive medications. The catheter usually terminates at the superior vena cava—right atrial border and is, therefore a measure of right atrial pressure (secondarily, right ventricular function) and superior vena cava venous pressure. The CVP is elevated in conditions that increase venous pressure or right atrial pressure, such as volume overload, heart failure, or elevated pulmonary artery pressures. The CVP is decreased in conditions that decrease venous pressure or right atrial pressure, such as low intravascular volume (e.g., shock, dehydration, hemorrhage). The CVP waveform consists of three upward "waves" and downward "descents." The a wave is produced by right atrial contraction. The c wave is produced by tricuspid valve closure and ventricular contraction. As the right ventricle continues to contract, right atrial pressure decreases, forming the x descent. The v wave ascent is formed as the right atrium fills with venous blood during late systole. Finally, the y descent is formed in early diastole as the tricuspid valve opens and blood flows from the right atrium to right ventricle.

Question: 44

The family of a patient with terminal leukemia is beginning discussions with the medical team about limiting further medical interventions and end-of-life care. The mother of the patient is struggling with feelings of "giving up" on her child's chances for recovery and asks for advice. Which of the following actions by the critical care nurse is most appropriate in this situation?

- A. Tell the mother what you would do if your child was in a similar situation.
- B. Tell other family members that the mother needs convincing about the plan of care.
- C. Arrange a conference to review treatment options, prognosis, and social support.
- D. Tell the mother that she needs to make decisions on her own.

Answer: C

Explanation:

An important role of the pediatric critical care nurse is assisting patients and families obtain the information and support they need to be a part of treatment decisions. There are two philosophical foundations from which the nurse may use his or her advocacy and moral agency obligations to the patient. One model emphasizes advocating for the patient and family. In other words, the nurse advocates for the pathway that he or she believes is in the best interest of the patient or family. A different model, sometimes referred to as the synergy model, involves the nurse advocating from the point of view of the patient and family. In other words, the nurse advocates for the course that the patient and family want but are unable to articulate themselves. Particularly with regard to issues involving end-of-life care, the family and patient need to be supported in informed decision-making so that they can make the best decision in keeping with their family's values and beliefs.

Question: 45

A 16-year-old boy is involved in a motor vehicle accident. Initial assessment reveals an intoxicated adolescent with an obvious deformity of his right wrist. The physician examines the patient and finds no cervical spine tenderness. After cervical spine x-rays are interpreted as normal, the patient asks to have his cervical spine immobilization collar (c-collar) removed. Appropriate management of this patient consists of

- A. removing the c-collar because the x-rays are normal.
- B. leaving the patient in a c-collar until his wrist injury has healed.
- C. removing the c-collar after immobilization of his wrist injury.
- D. leaving the c-collar in place until his wrist injury is stabilized and he is no longer intoxicated.

Answer: B

Explanation:

Cervical spine evaluation in the pediatric trauma patient may be challenging, depending on the patient's ability to cooperate with a detailed examination and the presence of other injuries. Physical examination of the cervical spine is indicated in all pediatric trauma patients. Radiologic evaluation of the cervical spine (e.g., computed tomography scan, plain x-ray) is indicated for patients who have focal neurologic abnormalities consistent with a spinal cord injury, altered mental status, neck pain or tenderness, or significant distracting injury. Cervical spine injury may be ruled out with clinical examination of the patient who is developmentally able to cooperate with detailed cervical spine and neurologic examination, has normal mental status, including absence of acute intoxication; and has no major distracting injuries. The patient described in the question is acutely intoxicated, has a major distracting injury (presumed wrist fracture), and therefore, should not be cleared for cervical spine injury clinically until he is no longer intoxicated and his wrist injury has been immobilized, even if x-rays appear normal.

Question: 46

The most accurate statement about acute kidney injury is which of the following?

- A. Nephrotoxic drugs do not contribute to acute tubular necrosis.
- B. Prerenal injury occurs secondary to inadequate renal perfusion.
- C. Prerenal injury is irreversible even when recognized and treated early.
- D. Acute kidney injury is always associated with poor urine output.

Answer: C

Explanation:

Acute kidney injury can be divided into three general categories based on the underlying cause, with a decrease in glomerular filtration rate (GFR) as the final common problem in all three broad categories. Prerenal injury describes impairment in renal blood flow (perfusion), leading to decreased GFR in the presence of normal nephrons and glomeruli. This is the most common form of acute kidney injury in the pediatric population and is usually seen in the setting of hypovolemic dehydration. Intrarenal injury (e.g., acute tubular necrosis) is characterized by decreased GFR secondary to intrinsic renal dysfunction, as occurs with glomerulonephritis, medication toxicity, asphyxia, and hemolytic uremic syndrome. Postrenal injury is characterized by decreased GFR secondary to obstruction of urinary outflow from the kidney, most commonly

the result of congenital abnormalities of the urinary tract in the pediatric population. Acute kidney injury has four stages: onset, oliguric/ anuric, diuretic, and recovery.

Question: 47

The critical care nurse is preparing to place a peripheral intravenous (IV) line in a developmentally normal 3-year-old boy. The most appropriate way to prepare this patient for the procedure is to

- A. show him each of the pieces of equipment used in the procedure and describe in detail for what each one is used.
- B. have the family distract the patient while the IV is placed without any warning or explanation.
- C. briefly describe the procedure, using simple language before placing the IV with the family present.
- D. have the family leave the room so that another nurse can help restrain the patient for the IV placement.

Answer: C

Explanation:

Understanding the expected developmental capabilities in a given age-group in conjunction with assessment of the individual patient is important in formulating the best plan for helping both patients and families through unfamiliar and potentially painful medical interventions. The average 3-year-old patient can generally speak in full sentences and understands simple explanations and instructions. They have a very basic understanding of time (e.g., now, soon, later) and enjoy repetition in stories and activities. They also enjoy being given simple choices between two options and enjoy exploring the world. For the typical 3-year-old, placement of a peripheral intravenous line should be preceded by a brief and simple description of the procedure with the family present. Some 3-year-old patients may enjoy practicing the procedure on a stuffed animal or exploring some of the equipment that will be used. Asking the family to leave during a painful and potentially scary procedure is not appropriate and will likely result in reduced patient cooperation.

Question: 48

A 10-year-old girl intubated in the critical care unit develops pneumonia

- a. The critical care nurse notices that the patient is coughing more and that the breath sounds have become coarser. Oxygen saturation has decreased from 97% to 95% with no recent change in ventilator settings. Which of the following interventions is most appropriate at this time?
- A. Suction the endotracheal tube
 - B. Increase the patient's sedative infusion rate
 - C. Obtain a chest x-ray
 - D. Notify the physician

Answer: A

Explanation:

Primary pneumonia or ventilator-associated pneumonia in the ventilated patient can lead to thick, copious airway secretions that may interfere with the patient's ventilation and oxygenation, as well as contribute to the overall stress response in the critically ill patient. Frequent repositioning, maximal humidity

in the ventilator circuit, chest physiotherapy, and frequent airway suctioning as tolerated can both prevent and help treat infected secretions in the ventilated patient with pneumonia. Although obtaining a chest x-ray may be revealing in this patient, suctioning the endotracheal tube first may correct the problem and should be tried first. Increasing the patient's sedation will likely increase patient comfort but may contribute to further pooling of lung secretions because of decreased patient movement and coughing. Although this patient has had a change in status about which the physician may want to be notified, the patient is not rapidly deteriorating, and a trial of airway suctioning is reasonable first.

Question: 49

All of the following clinical scenarios are likely to be associated with the syndrome of inappropriate antidiuretic hormone secretion EXCEPT

- A. diabetes mellitus.
- B. traumatic brain injury.
- C. medication effect.
- D. pneumonia.

Answer: A

Explanation:

The syndrome of inappropriate antidiuretic hormone (SIADH) may complicate a variety of medical conditions, including central nervous system disease, malignancy, and pulmonary disease. In the pediatric patient, SIADH is most commonly seen with meningitis, brain injury, and the postoperative period. Numerous medications may also cause SIADH in the pediatric population. Patients with diabetes mellitus may have decreased serum sodium levels because of the effect of hyperglycemia on serum sodium, but SIADH is not generally associated with diabetes mellitus. The primary derangement in SIADH is inappropriate elevation of antidiuretic hormone (vasopressin) levels in the setting of euvolemia, leading to increased free-water absorption in the kidneys and a dilutional hyponatremia. Serum osmolality is low, urine is inappropriately concentrated, and urine sodium excretion is elevated.

Question: 50

A critical care nurse is taking care of a patient with septic shock who develops diffuse mucosal bleeding, peripheral venous thromboses, and renal failure consistent with disseminated intravascular coagulation (DIC). Which of the following laboratory findings is most consistent with DIC?

- A. Normal prothrombin time (PT) and partial thromboplastin time (PTT)
- B. Thrombocytosis (elevated platelet count)
- C. Normal fibrin degradation products
- D. Prolonged PT and PTT

Answer: D

Explanation:

Disseminated intravascular coagulation (DIC) may be seen in association with virtually any serious medical condition, such as trauma, sepsis, pancreatitis, malignancy, and drug or toxin reactions. Whatever the underlying trigger, DIC is characterized by activation of the systemic coagulation cascade, leading to microthrombus and fibrin deposition in small blood vessels and often resultant multiorgan failure. Continued activation of the coagulation cascade results in consumption of platelets, fibrin, and clotting factors, which then leads to significant bleeding. Thus, DIC is characterized by simultaneous thrombosis and hemorrhage. Typical lab findings in DIC include prolonged prothrombin time and partial thromboplastin time and thrombocytopenia. Elevations in D-dimer and fibrin degradation products reflect fibrinolysis of the microthrombi associated with DIC.

Question: 51

A nurse colleague is beginning a new medication on one of his primary patients and says, "I have not hung this medication in a while, and I cannot remember if it is compatible with the intravenous fluids this patient is receiving." The critical care nurse has had a lot of recent experience with that particular medication and its compatibility profile. The most appropriate response by the critical care nurse is to

- A. offer to help, share the knowledge that would help with this particular case, and remind the nurse about other available resources.
- B. stay quiet, and let him find the information he needs so that he can learn to be independent.
- C. let the nursing supervisor know that this nurse needs more training before he cares independently for critical care patients.
- D. hang the medication for the nurse to make sure it is done properly.

Answer: A

Explanation:

Withholding information that may be helpful to a colleague is inappropriate and unprofessional, particularly when it pertains to immediate patient care. The most effective teamwork and collaboration occur when there is a combination of independent information-seeking, peer teaching, and mentoring. Alerting a supervisor in a punitive way when a colleague appropriately seeks additional information in caring for a patient is not necessary and will likely harm the working relationship between health care providers. Taking over the task for which a colleague is asking for help may solve the problem of the moment, but it will not contribute to the learning and development of the colleague's skill and experience.

Question: 52

An 8-year-old girl with insulin-dependent diabetes is hospitalized for an unrelated illness and tells the nurse that she would like to learn how to administer her own insulin; however, her parents feel that she is too young to manage such a serious chronic medical condition. The best action for the nurse in this case is to

- A. arrange for a diabetic teaching refresher, involving the entire family and the endocrine team.
- B. tell the girl that her parents' rules need to be respected.
- C. arrange for insulin teaching for the patient without informing the parents.

D. make note in the chart of the patient's stated preference. and let the medical team address it.

Answer: A

Explanation:

An important part of being an effective patient advocate is assisting patients and families in using all of the resources available to them with regard to education about health maintenance, disease treatment and prevention. and the treatment plan. Particularly as the developmental abilities of the pediatric patient change over time. families often need updates in chronic disease management teaching. In this case. the nurse's responsibility in advocating for the patient should lead the nurse to seek out age-appropriate resources in a way that respects the family's individual preferences and values. Deflecting this issue to the physician team is not necessarily inappropriate but risks inadequate resolution of an important patient care issue.

Question: 53

Which of the following signs indicates right-sided heart failure?

- A. Decreased central venous pressure
- B. Pulmonary edema
- C. Enlarged left ventricle on chest x-ray
- D. Hepatomegaly

Answer: D

Explanation:

Congestive heart failure is defined as the inability of the heart to pump cardiac output that is adequate to meet the body's metabolic demands. Initially, the sympathetic nervous system triggers a series of responses to compensate for inadequate cardiac output, such as increased heart rate. preload, and afterload. Renal compensation includes sodium and water retention, leading to increased preload. Ultimately, these adjustments lead to further cardiac dysfunction as the impaired heart attempts to deal with increased demand. With left ventricular failure, fluid backs up into the pulmonary circulation, leading to pulmonary edema. shortness of breath, orthopnea, enlarged left atrium and ventricle, and dyspnea on exertion. With right ventricular failure. which may occur secondary to left ventricular failure, fluid backs up into the systemic circulation. This leads to increased central venous pressure, hepatic congestion, peripheral edema. ascites, neck vein distention, and an enlarged right atrium and ventricle.

Question: 54

The critical care nurse is taking care of a 14-year-old patient who is being treated for status asthmaticus. He has been intubated for 10 days when he develops bloody gastric aspirates and melen

- a. Acute stress gastritis secondary to prolonged intubation is suspected as the most likely etiology of the gastrointestinal bleeding. Appropriate initial management of this patient consists of
- A. intravenous vasopressor administration.
 - B. intravenous steroid administration.

- C. intravenous ranitidine administration.
- D. decreased bronchodilator administration.

Answer: C

Explanation:

The critically ill pediatric or adult patient is at increased risk for developing erosions of the gastric mucosa with associated bleeding as a result of destruction of the usual protective gastric barrier. Clinically, stress gastritis may present as coffee-ground or bright red hematemesis, melena, or a falling hematocrit. Prevention of stress gastritis may be improved with prophylactic administration of sucralfate or H₂ blockers (e.g., ranitidine). Proton pump inhibitors may also be administered for prevention of stress gastritis but may be less effective than H₂ blockers or sucralfate because of the specific pathophysiology of stress gastritis. Treatment of stress gastritis includes proton pump inhibitors (e.g., pantoprazole), as well as sucralfate, H₂ blockers, and the administration of blood products for severe bleeding.

Question: 55

A 10-year-old healthy boy receives several doses of intravenous hydromorphone for a closed fracture reduction. Soon after the procedure has ended, his family calls the nurse into the room. On arrival, the nurse finds the patient unresponsive despite attempts to awaken him. Heart rate is 87 beats/min with a strong peripheral pulse; respiratory rate is 8 breaths/min; and oxygen saturation is 85% on room air. After administering supplemental oxygen and initiating bag-mask ventilation, the critical care nurse should next do which of the following?

- A. Administer intravenous naloxone
- B. Arrange for endotracheal intubation
- C. Administer intravenous flumazenil
- D. Begin chest compression

Answer: A

Explanation:

The patient described in the question is experiencing central nervous system and respiratory depression secondary to intravenous narcotic administration in association with acute fracture reduction. It is common for a patient who received several doses of intravenous analgesia during a painful procedure to develop respiratory depression once the painful procedure is completed. Naloxone is an opioid antagonist, which is indicated for patients with respiratory depression in the setting of opiate-induced respiratory or central nervous system depression. It is also commonly used as a diagnostic and therapeutic tool when given empirically in the unresponsive patient without known etiology. Naloxone may be administered intravenously (fastest onset), subcutaneously, or intramuscularly. Onset is rapid, and a response is seen within 2 minutes of intravenous administration. Repeat doses may be required. Naloxone may trigger an acute opioid withdrawal syndrome when given to the opioid-dependent patient. Flumazenil is indicated for reversal of benzodiazepine toxicity. Endotracheal intubation may be required if this patient does not respond to bag-mask ventilation and naloxone administration. Chest compression is not indicated in the patient with adequate heart rate and peripheral pulses.

Question: 56

Which of the following statements about supplemental oxygen delivery is most accurate?

- A. The reservoir bag on a nonrebreather mask does not need to be inflated during use
- B. Nasal cannula is the most effective form of supplemental oxygen delivery in the patient with significant hypoxemia
- C. Oxygen by simple face mask should be given with a flow rate of at least 5 L/min to avoid carbon dioxide accumulation in the mask
- D. Patients requiring supplemental oxygen are not given oral nutrition until they have been weaned to room air

Answer: C

Explanation:

The best method of supplemental oxygen delivery in spontaneously breathing patients depends on multiple factors, including their oxygen requirement, work of breathing, and their ability to tolerate the delivery device. Nasal cannula allows for oxygen flow rates of 0.1–5 L/min with a maximal fraction of inspired oxygen (FiO₂) of around 45%. The simple face mask allows for FiO₂ up to about 60% and needs to be administered at a flow rate of at least 5 L/min to avoid carbon dioxide (CO₂) accumulation in the mask. The nonrebreather (NRB) mask allows for an FiO₂ up to around 90% at 8–10 L/min. If the reservoir bag is not inflated with oxygen, the patient does not have an adequate oxygen source. A one-way valve in the NRB mask avoids inhalation of room air and reinhalation of exhaled CO₂. The Venturi (air-entrainment) face masks allow for high flow oxygen delivery at a settable FiO₂ up to around 50%; this type of mask reduces the risk of CO₂ retention relative to the NRB mask.

Question: 57

Required elements for the determination of pediatric brain death include all of the following EXCEPT

- A. lack of spontaneous respiratory effort.
- B. absence of corneal, gag, and cough reflexes.
- C. body temperature below 95°F (35°C)
- D. absence of a treatable and reversible cause of coma.

Answer: C

Explanation:

Guidelines for the determination of pediatric brain death were established in 1987 by the Task Force for the Determination of Brain Death in Children and consist of the following elements: absence of a reversible and treatable cause, coexistent coma and apnea, absence of brain stem function (i.e., fixed pupils, absent corneal/gag/cough reflex), absence of hypothermia, absence of movement (aside from spinal cord reflex withdrawal), and a consistent examination over observation period (age-dependent). Electroencephalogram is often used as a supportive examination and demonstrates electrocerebral silence (absence of brain activity) in brain death. Cerebral blood flow studies may also be used but may be misleading. The importance of a period of clinical observation is underlined by cases where examination soon after the initial insult was consistent with brain death, but re-examination revealed some recovery.

Question: 58

A patient in the ICU is intubated and receiving inhaled nitric oxide for severe pulmonary hypertension. The nurse will need to monitor the patient for which one of the following adverse effects of nitric oxide administration?

- A. Hypercapnia
- B. Oxygen toxicity
- C. Methemoglobinemia
- D. Volume overload

Answer: C

Explanation:

Methemoglobinemia occurs when hemoglobin loses its iron molecule, forming methemoglobin, which is incapable of binding and carrying oxygen to the cells. Inhaled nitric oxide produces vasodilation of the pulmonary vasculature. It does not cause hypercapnia, oxygen toxicity, or volume overload.

Question: 59

The critical care nurse overhears the parents of a patient with a newly diagnosed malignancy planning to take their child out of the hospital without informing anyone because they believe that a visit with their religious healer will cure the child's malignancy. The nurse's best course of action in this case is which of the following?

- A. After informing the medical team about what was overheard, speak with the parents to gather more information about their concerns and beliefs
- B. Let the parents know what was heard, and tell them a child protective services referral is being made immediately
- C. Arrange for a staff member to remain outside the patient's room to ensure that they do not leave against medical advice
- D. Inform hospital security that the parents must be removed from the patient's room because they are endangering their child

Answer: A

Explanation:

Cultural and religious awareness and sensitivity are crucial elements in the ability of the critical care nurse to advocate for the preferences of the patient and family. Attempting to gather more information from the family in this case regarding their values and religious beliefs as they pertain to their child's illness is likely to be helpful in both understanding their perspective and helping them articulate it to the medical team. That being said, the nurse can anticipate a potentially serious ethical conflict in this case with regard to the possible harm to the patient's survival if the family refuses to consider medical treatment for a serious diagnosis. Immediate referral to child protective services is not appropriate in this case, although in a case such as this one, ultimately a child advocate will get involved. Similarly, surreptitiously blocking the exit or attempting to

remove the family is neither ethical nor appropriate.

Question: 60

An 8-year-old child with chronic renal failure has a peritoneal dialysis catheter placed. Several weeks later, she develops abdominal tenderness and fever. To assess for bacterial peritonitis, which of the following procedures or lab results would be most helpful?

- A. Abdominal CT scan
- B. Complete blood count
- C. Blood culture
- D. Peritoneal fluid cell count and culture

Answer: D

Explanation:

Bacterial peritonitis is a known complication of peritoneal dialysis and may occur spontaneously or as a result of contamination of the dialysate. Spontaneous bacterial peritonitis may also develop in patients with chronic ascites. Clinically, bacterial peritonitis may present with fever, abdominal pain and tenderness, ileus, diarrhea, worsening renal failure, or it may be, in some cases, asymptomatic. Diagnosis is confirmed with analysis of peritoneal fluid, which demonstrates an elevated neutrophil count with a positive bacterial culture. Supportive findings in the peritoneal fluid include decreased pH and elevated lactate levels. Blood culture may also be positive in patients with bacterial peritonitis and serum white blood cells are often elevated, but the definitive diagnostic evaluation remains assessment of peritoneal fluid.

Question: 61

A 5-year-old child who is evaluated for placement of myringotomy tubes is noted to be hypertensive. Further assessment reveals a child who appears well and is in no apparent distress. Heart rate, respiratory rate, and oxygen saturation are within normal limits. Cardiac examination reveals a 2/6 systolic murmur heard best at the lower left sternal edge and radiating to the left scapular area. Carotid pulses are 2+, but femoral pulses are difficult to detect. Four-limb blood pressure measurements are as follows:

Right upper extremity: 130/89 mmHg

Left upper extremity: 132/88 mmHg

Right lower extremity: 90/42 mmHg

Left lower extremity: 84/40 mmHg

Given this clinical scenario, the patient is likely to have which of the following congenital heart defects?

- A. Ventricular septal defect
- B. Coarctation of the aorta
- C. Atrial septal defect
- D. Pulmonary valve stenosis

Answer: B

Explanation:

Coarctation of the aorta is a congenital heart defect characterized by narrowing of the proximal aorta. Severe cases generally present in early infancy with congestive heart failure and may occur in association with other congenital heart defects. Less severe cases may not present until later childhood or adulthood when hypertension or a murmur is noted at a routine visit. Symptoms may include shortness of breath with exertion, lower extremity weakness or cramping with exertion, chest pain, headache, and nosebleeds. Four-limb extremity blood pressure measurements reveal differential blood pressures between the upper and lower extremities (at least 20 mmHg difference). Neonatal patients may also have a difference in preductal and postductal pulse oximetry (higher preductal oxygen saturation). If the coarctation is proximal to the origin of the left subclavian artery, right arm blood pressure will be elevated relative to the left arm and both lower extremities. Chest x-ray may show cardiomegaly (secondary to left ventricular hypertrophy) and rib notching secondary to enlarged collateral vessels in the older patient.

Question: 62

Which of the following statements about antiarrhythmic medications is most accurate?

- A. All antiarrhythmic medications work by prolonging repolarization time
- B. Adenosine is the treatment of choice in Wolff-Parkinson-White syndrome
- C. Calcium-channel blockers are the treatment of choice for ventricular arrhythmias
- D. A common complication of antiarrhythmic medications is cardiac arrhythmias

Answer: D

Explanation:

There are four general classes of antiarrhythmic medications, which can be differentiated by their primary mechanism of action, although several medications work by multiple pathways (e.g., amiodarone). Class I drugs are sodium-channel blockers and act by decreasing automaticity and conduction velocity. This class of medication has a greater effect at higher heart rates and includes procainamide, lidocaine, and quinidine. Class II drugs are beta-blockers (e.g., esmolol). Class I, II, and III antiarrhythmics may be used to treat supraventricular or ventricular arrhythmias. Class III drugs are potassium-channel blockers and act by delaying repolarization and increasing refractory time (e.g., sotalol). Class IV drugs are calcium-channel blockers and act via blockade of the atrioventricular (AV) node. Calcium-channel blockers are used to treat supraventricular arrhythmias (not ventricular arrhythmia) and are contraindicated in patients with Wolff-Parkinson-White syndrome. Adenosine decreases automaticity and increases refractory time by slowing conduction through the AV node; it is associated with an increased risk of degeneration into a life-threatening ventricular tachyarrhythmia when used in patients with Wolff-Parkinson-White syndrome.

Question: 63

A 2-year-old child with type I glycogen storage disease is admitted with dehydration related to an acute gastroenteritis. Assessment reveals a lethargic, diaphoretic toddler with a peripheral intravenous line in place. Heart rate is 170 beats/min. Bedside glucose is 36 mg/dL. The patient is continuing to vomit despite antiemetic therapy. The most appropriate way to treat this patient's hypoglycemia is

- A. oral glucose replacement.
- B. central line placement for high concentration dextrose administration at a rate of 18—20 mg/kg/min.
- C. an intravenous dextrose bolus 0.25—0.5 g/kg followed by continuous dextrose administration at a rate of 8—10 mg/kg/min.
- D. intermittent intravenous dextrose boluses as needed for hypoglycemia.

Answer: C

Explanation:

Hypoglycemia in the pediatric patient is most often seen in the neonatal period but may also be seen in older pediatric patients with inborn errors of metabolism, adrenal insufficiency, and drug or toxin ingestion. In the hypoglycemic patient who is awake and has intact airway protective reflexes, oral administration of high-sugar fluids may be adequate to correct hypoglycemia. In the unstable patient (e.g., altered mental status, hypoglycemic seizure, hemodynamic instability), intravenous administration of dextrose is the initial treatment of choice in most cases. Generally, an initial bolus of 0.25—0.5 g/kg dextrose is given to bring serum glucose over 50 mg/dL rapidly. Depending on the etiology of the patient's hypoglycemia, ongoing dextrose administration may also be warranted. The patient described in the question has an underlying glycogen storage disease and is continuing to vomit in the setting of infectious gastroenteritis; given this patient's dependence on oral intake to maintain adequate serum glucose levels, continuous intravenous dextrose administration should be continued until the patient is able to tolerate oral hydration.

Question: 64

A 14-year-old patient is receiving a packed red blood cell transfusion after abdominal surgery. Halfway through the transfusion, he develops fever, chest pain, flank pain, and nausea. The next action by the critical care nurse is to

- A. administer intravenous diphenhydramine.
- B. slow the rate of the transfusion.
- C. stop the transfusion immediately.
- D. administer oral acetaminophen.

Answer: C

Explanation:

The patient described in the question is demonstrating signs of a hemolytic transfusion reaction. Hemolytic transfusion reactions result from antibodies in the patient's plasma targeting antigens on the donor red blood cells. The most common cause of acute hemolytic transfusion reactions is incompatible ABO type between donor blood cells and the patient. Hemolytic transfusion reactions are usually symptomatic before the transfusion is complete. Symptoms include abrupt onset of fever, chills, back pain, chest pain or tightness, nausea, and agitation. Patients may progress rapidly to renal failure, disseminated intravascular coagulation, and complete cardiovascular collapse. The first step of treatment in any suspected transfusion reaction is stopping the infusion immediately. The donor unit should be inspected to check if the patient was the intended recipient and then sent back to the blood bank with a patient's blood sample for incompatibility testing. Further treatment after the infusion is stopped is supportive and usually includes intravenous crystalloid administration and medication to maintain renal blood flow (e.g., furosemide, dopamine). Nonhemolytic

febrile transfusion reactions are the most common transfusion reactions and rarely progress to rapid decompensation.

Question: 65

In caring for a 4-year-old patient with ongoing status epilepticus, the critical care nurse expects which of the following treatment measures after benzodiazepine administration?

- A. Intravenous phenytoin or fosphenytoin
- B. Intravenous propofol infusion
- C. Intravenous hydrocortisone
- D. External cooling

Answer: A

Explanation:

Caring for the patient with status epilepticus involves more than medication Administration. Careful attention is required to ensure that the seizing patient has an open airway and adequate respiratory effort. Proper positioning of the patient (often in lateral decubitus position) is necessary to avoid airway obstruction and to allow for better airway protection if the patient vomits. Suction, oxygen, and advanced airway equipment should be readily available, and intravenous access should be obtained. There is generally a standardized approach to the medication management of status epilepticus. Benzodiazepines are the first-line medication of choice; they can be given rectally (e.g., rectal diazepam) or intravenously and are often repeated every few minutes for ongoing seizure activity. If the seizure continues despite benzodiazepine administration, fosphenytoin/phenytoin or phenobarbital are the usual second-line medications. Phenobarbital is generally preferred for an infant patient, while fosphenytoin is usually preferred for the older child. If seizure activity continues, anesthesia with continuous barbiturate, propofol, or midazolam may be used.

Question: 66

A critical care nurse is taking care of a 3-week-old infant born at 29 weeks gestation. The infant has been progressing well with a gradual advance in enteral formula feedings over the last several days. However, the infant unexpectedly had several episodes of apnea and one episode of small-volume emesis just before a scheduled feeding. Which of the following actions by the critical care nurse should be done next?

- A. Continue to advance the infant's enteral feeding volume, according to the existing orders
- B. Continue to feed the infant as scheduled, but hold off on the ordered increase in formula volume
- C. Hold off on giving the scheduled feeding until the infant can be examined and evaluated further
- D. Change the infant's formula type with the next feeding to decrease the likelihood of further vomiting

Answer: C

Explanation:

Premature infants are at increased risk for multiple neonatal complications, including necrotizing enterocolitis (NEC) and sepsis. The early symptoms of worsening clinical status are often subtle in the neonate.

Symptoms can include nonspecific behavioral changes, temperature instability, feeding intolerance, apnea, and respiratory distress. In this case, an infant who had been stable is showing signs of a potential deterioration and requires further assessment before routine care is continued. Given the onset of symptoms in the setting of enteral feeding advancement, evaluation for NEC is warranted. Initial assessment should include a complete physical examination, abdominal radiographs to evaluate for pneumatosis or signs of intestinal perforation, and laboratory studies (complete blood count and chemistry panel). Feedings should be held until the infant has improved and necrotizing enterocolitis is either treated or ruled out. Evaluation for sepsis is also appropriate in this infant's case.

Question: 67

A 2-year-old child is admitted with suspected meningococci

a. The patient deteriorated

rapidly in the emergency department and was transferred to the critical care unit after receiving one 20 mL/kg normal saline bolus and intravenous antibiotics. Initial assessment reveals a lethargic, ill-appearing, poorly perfused child with numerous purpuric skin lesions. Heart rate is 195 beats/min, respiratory rate is 44 breaths/min, and blood pressure is 70/31 mmHg. The most appropriate next step in treating this patient's hypotension is

A. positive pressure ventilation.

B. additional 20–40 mL/kg of intravenous normal saline.

C. intravenous dopamine infusion.

D. intravenous corticosteroid administration.

Answer: B

Explanation:

The clinical condition of the patient described in the question is consistent with uncompensated septic shock, likely secondary to meningococci given the presence of purpura. Although this patient will likely require intubation and mechanical ventilation in addition to vasopressor administration, initial management of this patient's hypotensive shock should consist of aggressive intravascular fluid replacement with 60–80 mL/kg isotonic crystalloid solution (e.g., normal saline). The 20 mL/kg given thus far is an inadequate volume of fluid resuscitation in this patient, given the ongoing hemodynamic instability with signs of end-organ hypoperfusion. Although intravenous corticosteroids may be administered in the patient with adrenal hemorrhage in association with meningococci (Waterhouse-Friderichsen syndrome), initial therapy consists of intravascular volume administration.

Question: 68

A critical care nurse has had difficulty interactions in personal and social settings with a colleague who is the unit's chest tube nursing care "expert." The nurse is having difficulty with the chest tube of one of the medically complex patients. Which of the following actions by the critical care nurse is most appropriate in this case?

A. Ask a different nurse colleague for assistance, so that a potentially difficult personal interaction can be avoided

B. Ask to be removed from this patient's care to avoid having to manage a difficult chest tube

- C. Ask someone else to ask the chest tube care expert for help and then have him or her convey the answer to the primary nurse
- D. Seek out assistance from the chest tube expert to most effectively obtain the resources needed to care for this patient

Answer: D

Explanation:

It is particularly important in the critical care setting for the nurse to use all of the resources available to provide the best possible patient care. This includes working cooperatively with other staff members across multiple disciplines to address the patient or family's medical needs. The only appropriate action in this case is to maintain professionalism and seek out the best resource available, regardless of a history of interpersonal difficulties. The critical care pediatric patient deserves a team that can work together to provide good care.

Question: 69

An intubated patient is monitored with continuous capnography (end-tidal carbon dioxide [EtCO₂] monitoring). Which of the following conditions is most likely to be associated with an increase in the patient's baseline measured EtCO₂?

- a. Cardiac arrest
- b. Fever and hyperthermia
- c. Hyperventilation (increased respiratory rate)
- d. Acute pulmonary embolus

Answer: B

Explanation:

Continuous capnography allows for very rapid detection of changes due to the extremely rapid diffusion of carbon dioxide (CO₂) across the alveolar-capillary membrane. End-tidal CO₂ (EtCO₂) values are a reflection of tissue CO₂ production, delivery of systemic blood to the pulmonary circulation, and alveolar ventilation. An increase in EtCO₂ is, therefore, indicative of increased CO₂ production or a derangement in the clearance of CO₂ (e.g., hyperthermia, seizure, burn injury, reperfusion, hypoventilation). A decrease in EtCO₂ is indicative of decreased CO₂ production (e.g., sedation/anesthesia), enhanced clearance (e.g., hyperventilation), ventilation of poorly perfused alveoli, or decreased cardiac output (i.e., decreased delivery of systemic blood to the pulmonary circulation). A sudden increase in EtCO₂ is generally seen with malignant hyperthermia reactions or ventilation of a previously unventilated lung. A gradual increase in EtCO₂ may be seen with rising body temperature or hypoventilation. A sudden fall in EtCO₂ usually indicates equipment failure or dislodgement. Continuous exponential decrease in EtCO₂ is seen with pulmonary embolism, a rapid fall in blood pressure, or cardiac arrest.

Question: 70

A 10-year-old girl is admitted with newly diagnosed type I diabetes mellitus, moderate dehydration, and diabetic ketoacidosis. The critical care nurse expects to find all of the following signs or symptoms on physical examination EXCEPT

- A. tachypnea.
- B. tachycardia.
- C. bounding peripheral pulses.
- D. lethargy.

Answer: C

Explanation:

Diabetic ketoacidosis (DKA) is almost always associated with significant dehydration secondary to the osmotic diuresis caused by hyperglycemia and fluid losses due to vomiting. Dehydration leads to tachycardia and poor peripheral perfusion; generally, distal extremities are cool and poorly perfused, and peripheral pulses may be weak or thready in the patient with significant dehydration. The lethargy often seen in patients with DKA is secondary to both dehydration and acidosis. Cerebral edema, a rare but potentially fatal complication of DKA, and corrective therapy, may also present with lethargy thus, the patient with DKA requires frequent serial neurologic examinations to identify signs of increased intracranial pressure as early as possible. Tachypnea and classic deep Kussmaul respirations are present as a compensatory mechanism for the primary metabolic acidosis associated with DKA. One would not expect bounding peripheral pulses in the dehydrated diabetic patient.

Question: 71

The nurse received a 17-year-old patient in the ICU postoperatively following a cholecystectomy. The patient has risk factors for malignant hyperthermia

a. The patient's vital signs are as follows:

Blood pressure: 155/96 mmHg

Heart rate: 96 bpm

Respiratory rate: 24

Oxygen saturation: 95% on 3 L by nasal cannula

Temperature: 98.9°F

Which one of the following should be included in the patient's postoperative care plan to prevent the complications of malignant hyperthermia?

- A. Place the patient on a cooling blanket postoperatively.
- B. Instruct the patient on using the incentive spirometer 10 times per hour while awake.
- C. Apply sequential compression devices to the bilateral lower extremities.
- D. Use continuous end-tidal CO₂ monitoring.

Answer: D

Explanation:

Malignant hyperthermia is a life-threatening genetic disorder that results in elevated temperature, acidosis, tachycardia, and muscle contractions after an at-risk patient receives specific anesthetic drugs or muscle relaxers. The hypermetabolism of cells leads to an increase in CO₂. End-tidal CO₂ monitoring can detect elevated CO₂ levels and malignant hyperthermia early, allow for early treatment, and prevent complications. The patient is afebrile; therefore, a cooling blanket is not necessary. Incentive spirometry is used to prevent atelectasis and pneumonia. Sequential compression devices are used postoperatively to prevent deep vein thrombosis.

Question: 72

Which of the following statements about parenteral nutrition is most accurate?

- A. Parenteral nutrition requires less frequent monitoring of serum electrolytes and glucose than enteral nutrition
- B. Total parenteral nutrition results in improved maintenance of normal intestinal function and structure compared with enteral nutrition
- C. A single bag of parenteral nutrition fluid can be stopped and restarted several times if other medications need to be administered
- D. Complications of total parenteral nutrition include catheter-related infection and cholestasis

Answer: D

Explanation:

Parenteral nutrition is indicated in the pediatric patient who is unable to tolerate full enteral feedings secondary to primary gastrointestinal disease (e.g., inflammatory bowel disease, short bowel syndrome, bowel obstruction) or serious systemic illness (e.g., sepsis, burns, trauma). Parenteral nutrition requires stable intravenous access and frequent monitoring of serum electrolytes, glucose, and liver function. In most cases, enteral nutrition is preferred whenever possible. Because of the risk of infection, parenteral nutrition bags need to remain a closed system (i.e., administration without interruption or addition over no more than a 24-hour period). Complications of parenteral nutrition include intravenous catheter-related problems (infection, thrombosis), cholestasis, and electrolyte or glucose abnormalities.

Question: 73

A 5-year-old child returns from the operating room after undergoing open drainage and irrigation of a septic hip joint. Several hours after returning from the recovery room, the child is crying and persistently complaining of hip pain despite his father's attempts to calm him and oral acetaminophen administration. Which of the following actions by the critical care nurse is most appropriate?

- A. Give a placebo (e.g., 5 mL normal saline) intravenously to assess if the child's agitation is mostly behavioral
- B. Ask the father to teach the patient how to use the age-appropriate pain scale (e.g., faces scale), and report back to you with the child's pain level
- C. Inform the patient and family that they should wait until the next dose of acetaminophen can be given so that the child does not become addicted to narcotics
- D. Administer pain medication as ordered, and teach the patient how to use the age-appropriate pain scale once he is more comfortable

Answer: D

Explanation:

The child described in the question is displaying both subjective and objective signs of discomfort after a surgical procedure despite attempted calming measures and oral acetaminophen administration. Placebo administration is inappropriate and unethical in the setting of acute pediatric pain. Age-appropriate pain scales are very helpful in the pediatric acute care setting and may even be used with very young patients. Although this patient is likely developmentally capable of learning to use a pain scale, asking the father to instruct the patient in its proper use or attempting to teach the patient how to use a pain scale when he is still experiencing significant pain is not ideal. Once the patient is more comfortable, it would be appropriate for the

critical care nurse to find the most appropriate pain scale and spend time instructing both the family and the patient how to use it. Although narcotic medications are potentially addictive, proper use in the setting of acute pain in the pediatric patient is not linked with narcotic addiction or inappropriate "drug-seeking" behavior.

Question: 74

All of the following patient factors are likely to interfere with successful weaning from mechanical ventilation EXCEPT

- A. inadequate nutritional status.
- B. deeply sedated patient.
- C. genetically small body habitus.
- D. neuromuscular disease.

Answer: C

Explanation:

Patients who have required mechanical ventilation for any prolonged period of time may be difficult to wean from the ventilator. Although the patient's pulmonary status is extremely important in determining whether a patient can be successfully extubated, there are multiple factors that come into play when considering a patient's ability to breathe independently. Pulmonary or cardiovascular disease, which significantly interfere with oxygenation, ventilation, or cardiac output, need to be minimized when possible for weaning and extubation to succeed. Conditions that interfere with the patient's respiratory drive or airway protective reflexes (e.g., excessive sedation, traumatic brain injury) may hamper successful weaning. Respiratory muscle weakness secondary to atrophy, suboptimal nutritional status, or neuromuscular disease will significantly impair weaning and successful extubation after mechanical ventilation. A small body habitus is not a major factor in weaning from a ventilator.

Question: 75

A healthy toddler is admitted to the critical care unit with a 2 -hour history of lethargy, vomiting, and bloody diarrhea

a. The child's mother reports that he ate a hamburger for dinner the night before, and "tried out" some of the mother's prenatal vitamins earlier that day. Assessment reveals a lethargic, tachycardic, hypotensive child with poor peripheral perfusion and diffuse abdominal tenderness. Laboratory evaluation reveals a profound metabolic acidosis with elevated anion gap, elevated white blood cell count, and elevated serum glucose levels. Platelet count, hematocrit, and serum creatinine are within normal limits. Given this information, the most helpful additional study is

- A. a stool culture.
- B. a serum iron level.
- C. a blood alcohol level.
- D. an erythrocyte sedimentation rate.

Answer: B

Explanation:

Iron ingestion remains a common cause of serious overdose in the pediatric population because of its highly toxic effects and widespread availability. Iron toxicity is due to corrosive gastrointestinal tract damage and direct cellular toxicity. Clinically significant iron poisoning is divided into four stages. The first stage (gastrointestinal) occurs within 6 hours of ingestion and is characterized by abdominal pain, vomiting, diarrhea (possibly bloody), and possibly hypovolemic shock. Stage (latent) occurs 6–24 hours after ingestion and is characterized by apparent clinical improvement. Stage three (metabolic/cardiovascular/shock) occurs 6–72 hours after ingestion and is characterized by the return of gastrointestinal symptoms, metabolic acidosis, altered mental status, shock, and coagulopathy. Stage four (delayed) occurs 2–6 weeks after ingestion and is characterized by scarring of the gastrointestinal tract. Ingestions of less than 20 mg/kg elemental iron are generally nontoxic. Patients with unknown or larger ingestions should have serum iron levels drawn 4–6 hours after ingestion. Serum iron levels of more than 300 mcg/dL are considered toxic. Treatment includes intravenous fluid administration, deferoxamine (chelating agent), vasopressors, and blood products as indicated.

Question: 76

A patient is being discharged after being hospitalized with a new-onset seizure disorder. His family is concerned that the school nurse will not know how to manage this disorder appropriately if the child has a seizure during the school day. The nurse's best response in this case is to

- A. tell the family to keep the child out of school until his seizures are well controlled.
- B. call the school district to ask if the nurses know how to manage children with seizure disorders.
- C. reassure the family that most school nurses have dealt with seizures before.
- D. assist the family in communicating with the school staff about this patient's specific care needs before the child returns to school.

Answer: D

Explanation:

Providing the best patient care often extends to working with agencies and organizations outside of the critical care or hospital setting. Assessment of the ability of outside institutions (e.g., school, day care) to provide the daily monitoring and care the patient requires after discharge may prevent complications or recurrence of the patient's illness or injury. In addition, the nurse is often able to provide helpful information to outside organizations about the individual patient or to find relevant resources that may be available. Patients and families often require assistance in dealing with insurance companies after hospital discharge as well.

Question: 77

A 10-year-old boy is admitted to the critical care unit with status asthmaticus. All of the following treatment options would be appropriate to include in this patient's initial plan of care EXCEPT

- A. inhaled bronchodilators.

- B. intravenous corticosteroids.
- C. inhaled ipratropium.
- D. intravenous propranolol.

Answer: D

Explanation:

The primary treatment for acute asthma is beta-agonist medication, such as albuterol sulfate. Beta-agonist bronchodilators stimulate the numerous beta receptors in the airways, leading to airway smooth muscle relaxation and reduced production of mucus. Beta agonists are generally delivered directly to the airways via the inhaled route, but intravenous beta agonists (e.g., terbutaline) may also be used in the critically ill asthmatic patient. Intravenous magnesium sulfate may also be administered to enhance airway smooth muscle relaxation. Corticosteroids are administered to decrease underlying airway inflammation and may help decrease pulmonary capillary leakage. They can be administered orally, but intravenous administration is generally preferred in the critically ill asthmatic. Ipratropium is an anticholinergic agent that enhances bronchodilation and decreases the production of mucus, particularly when used in conjunction with beta agonists. Propranolol, a beta-blocker medication, exacerbates bronchospasm and, therefore, is an unusual choice of drug for an asthmatic patient unless there are chronic underlying medical issues requiring beta blockade.

Question: 78

A 16-month-old boy presents with persistent cough after an older sibling shared peanuts with him earlier in the day. A family member reports that he had a witnessed choking episode without apnea or cyanosis. Physical examination reveals an alert, interactive toddler with mild suprasternal retractions and a frequent dry cough. Respiratory rate is 36 breaths/min, and oxygen saturation is 96% on room air. Auscultation of the chest reveals expiratory wheezing on the right. Standard two-view chest x-rays are normal. Appropriate management of this patient consists of

- A. bronchoscopy.
- B. Heimlich maneuver.
- C. nebulized betamethasone.
- D. observation in the inpatient setting.

Answer: A

Explanation:

Foreign body aspirations are common in mobile toddlers due to their propensity for putting food and other found items into their mouths. Commonly aspirated foods in the toddler population are nuts, hot dogs, hard candy, and grapes. Because of the anatomy of the upper bronchial tree, foreign body aspiration most commonly involves the right main stem bronchus. Clinical presentations range from chronic cough and recurrent pneumonia to complete respiratory arrest, depending on the location of the foreign body in the respiratory tract and associated airway edema. Physical examination may reveal cough, stridor, wheezing, retractions, and asymmetric breath sounds. Chest x-ray may be normal, as in this case, or may demonstrate air trapping on the involved side. Bilateral decubitus chest films may aid in detection of asymmetric air trapping

on x-ray. The patient described in the questions had a witnessed choking episode and has a physical examination consistent with an inhaled foreign body. Even in the setting of a normal chest x-ray, a symptomatic patient with a choking history generally requires a bronchoscopy for airway examination and foreign body removal.

Question: 79

A teenager with progressive glomerulonephritis and resultant renal failure develops muscle cramps, agitation, shortness of breath, and tingling sensations in his extremities. Which of the following conditions is the most likely etiology of these symptoms?

- A. Hypocalcemia
- B. Hypokalemia
- C. Panic attack
- D. Hypoglycemia

Answer: A

Explanation:

Chronic renal failure commonly leads to hypocalcemia due to both impaired renal production of calcitriol and reduced conversion of 25-OH vitamin D to 1,25-OH vitamin D (the active form of vitamin D). The body requires calcium for multiple physiologic processes, including muscle contraction and relaxation, nerve conduction, hormone secretion, and bone mineralization. Symptoms of hypocalcemia reflect dysfunction in these bodily and cellular functions: peripheral tingling sensation; muscle spasms, which may manifest as tetany; wheezing due to bronchospasm; voice changes from laryngospasm; irritability; and seizures. The Chvostek sign may be seen in up to 10% of hypocalcemic patients: when the skin over the exit of the facial nerve is tapped, the facial muscles on that side of the face contract. The Trousseau sign may also be elicited in the hypocalcemic patient; inflation of a blood pressure cuff to 20 mmHg above the patient's systolic blood pressure for several minutes leads to spasmodic flexion of the wrist and metacarpal and phalangeal joints.

Question: 80

The critical care nurse is most likely to expect therapeutic hypothermia to be part of the treatment plan in which of the following clinical scenarios?

- A. Septic shock
- B. Disseminated intravascular coagulation
- C. Coma secondary to drug overdose
- D. Traumatic brain injury with elevated intracranial pressure

Answer: D

Explanation:

Hypothermia is associated with several metabolic alterations, including decreased cerebral and myocardial metabolic demands, decreased release of inflammatory mediators, and decreased cell destruction. Clinical situations in which therapeutic hypothermia may be beneficial include traumatic brain injury and

patients who have return of spontaneous circulation after a witnessed cardiac arrest (especially ventricular fibrillation arrest). Eligible patients are actively cooled as quickly as possible to a goal body temperature of 32 for up to several days, depending on the clinical indication. Patients generally require continuous core body temperature monitoring and invasive hemodynamic monitoring. Sedation and neuromuscular blockade may be required for comfort and prevention of shivering. Therapeutic hypothermia is contraindicated in patients with coagulopathy because of the increased risk of coagulopathy, systemic infection because of an impaired immune response, and coma secondary to causes other than cardiac arrest or traumatic brain injury.

Question: 81

The mother and father of a patient in the critical care unit are divorced. The nurse notices that the parents are frequently arguing with each other when at the patient's bedside. Which of the following actions by the nurse is most appropriate?

- A. Find resources for the parents to help them deal with the stress of a critically ill child while coping with their interpersonal conflicts
- B. Inform the parents that they are not allowed to visit the patient at the same time
- C. Tell the parents they need to do more to support their child
- D. Tell the parents that you can empathize with their situation because you argue with your ex-spouse as well

Answer: A

Explanation:

Previously existing family conflict between caregivers is often exacerbated in the setting of a child's serious illness and may detract from the healing environment. Nursing attention to the well-being of the patient's family includes assisting with crisis management, conflict resolution, and compromises that adequately address the needs of all involved parties, including the patient. Unilateral decision-making, that leads to increased feelings of powerlessness in the patient's family members (e.g., telling the parents they cannot visit at the same time) is not appropriate unless all other avenues of conflict resolution have been explored and attempted. Empathy and compassion are important qualities upon which to draw when addressing family conflict, but it is not usually appropriate or particularly helpful to share details of one's personal family conflicts.

Question: 82

A 13-month-old boy with a tracheostomy suddenly becomes restless and develops severe respiratory distress and hypoxi

- a. The critical care nurse notices that the tracheostomy tube has accidentally been removed and is lying on the bed next to the patient. The next appropriate intervention is to
- A. observe the patient to see if he can breathe adequately without the tracheostomy.
 - B. replace the tracheostomy tube in the stoma.
 - C. suction the stoma site.
 - D. request a replacement tracheostomy tube from the supply center.

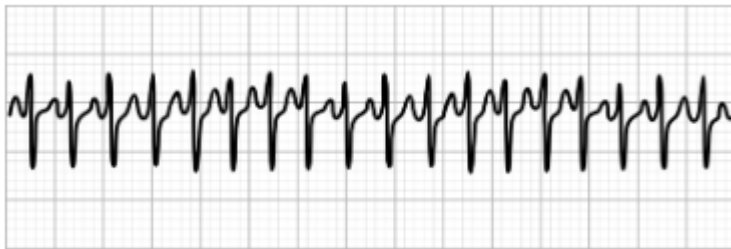
Answer: B

Explanation:

Accidental decannulation is a medical emergency in most tracheostomy-dependent patients. Signs of accidental decannulation include acute agitation and respiratory distress, which may progress rapidly to respiratory arrest if the patient is unable to breathe through the stoma site. If possible, the first-line treatment in accidental decannulation is replacement of the tracheostomy tube. Generally, an additional new tracheostomy tube is kept in proximity to the patient to allow for replacement in the case of decannulation or tube obstruction that cannot be cleared with suctioning or bag-trach ventilation. If there is not a clean replacement tube immediately available for the patient in respiratory distress, the old tube should be replaced in the stoma site for short-term use until the patient has been stabilized. Suctioning the stoma site is not indicated in the distressed patient After decannulation.

Question: 83

The critical care nurse is taking care of a 17-year-old patient who is admitted with dizziness and palpitations, which began 2 hours earlier. Vital signs are: heart rate, 180 beats/min; respiratory rate, 22 breaths/min; blood pressure 110/75 mmHg; and oxygen saturation, 97% on room air. Examination reveals an alert, pale, interactive young woman who is well perfused peripherally. Her electrocardiogram is shown below.



Vagal maneuvers are attempted without any change in clinical status. The critical care nurse expects the next intervention to be

- A. oral aspirin administration,
- B. continuous beta-blocker infusion.
- C. intravenous adenosine administration.
- D. synchronized cardioversion.

Answer: C

Explanation:

This patient's electrocardiogram demonstrates a regular, narrow-complex tachycardia without visible P waves, which is consistent with a paroxysmal supraventricular tachycardia (PSVT). With PSVT, there is an accessory electrical pathway near or within the atrioventricular (AV) node. When the patient is having an acute episode, there is conduction of the electrical impulse through both the normal pathway and the accessory pathway, resulting in a re-entrant repetitive circuit. Vagal maneuvers, such as the Valsalva maneuver, gagging, coughing, or stimulation of the diving reflex with ice on the face, may abort the tachycardia by slowing conduction through the AV node and interrupting the re-entrant circuit. When vagal maneuvers are ineffective, the first-line therapy in stable patients (as in this case) is intravenous adenosine. Beta blockers or calcium-channel blockers may also be used, but adenosine remains the usual initial pharmacologic treatment.

In the unstable patient (e.g., with congestive heart failure, hypotension, respiratory distress, cardiac ischemic changes), synchronized cardioversion should be used without delay.

Question: 84

The mother of a 4-year-old critically ill patient tells the nurse that she has not eaten in 3 days because she does not want to leave her daughter's side. Hospital policy states that visiting family members may not eat in the patients' rooms. The nurse's best action in this situation is to

- A. tell the mother to go get some food since her critically ill daughter will not know if she is there or not.
- B. find a place close to the patient's room where the mother can eat, and reassure her that she will be informed immediately if her daughter's condition changes.
- C. remind the mother that it will not be helpful to her daughter if she is not taking care of herself.
- D. tell the mother that arranging for family members to eat is not the nurse's responsibility.

Answer: B

Explanation:

Despite the highly specialized knowledge required to provide nursing care for the critically ill pediatric patient, a fundamental underpinning of nursing care remains a commitment to caring practices. In addition to providing a therapeutic and caring environment for the patient directly, consideration of the family's health and wellness is an important part of caring nursing practice. Flexibility with regard to hospital policy when possible and reassurance to family members about their child's care and communication plan assists family members in meeting their basic daily needs (e.g., sleep, meals) and maintaining the highest possible level of caregiver well-being.

Question: 85

A 4-year-old healthy child is admitted with dehydration in association with a gastrointestinal illness. The patient's family reports that she was well until 5 days ago, when she developed vomiting and diarrhea

a. After 1 day, the diarrhea became bloody. The family reports that she has not urinated in at least 24 hours. Assessment reveals an irritable, pale child who is tachycardic and mildly hypertensive with mild diffuse abdominal tenderness. Laboratory evaluation reveals the following:

White blood cells: 18,000/gL

Hb: 8 g/dL

Hct: 24%

Platelets: 54,000/uL

Nx 135 mEq/L

P: 6.0 mEq/L

Cl: 97 mmol/L

HCO₃⁻: 15 mmol/L

BUN: 48 mg/dL

Cr: 1.7 mg/dL

The most likely explanation for this patient's condition given the above laboratory values is

- A. irritable bowel syndrome.
- B. intussusception.
- C. hemolytic uremic syndrome.
- D. ureteral obstruction secondary to nephrolithiasis.

Answer: C

Explanation:

Hemolytic uremic syndrome (HUS) is characterized by acute renal failure, hemolytic anemia, and thrombocytopenia. Approximately 95% of pediatric cases follow a bloody diarrheal illness, usually *Escherichia coli* O157:H7. Classically, pediatric patients present with abdominal pain and a several-day history of diarrhea, which becomes bloody 1–2 days into the illness. Many patients also have vomiting, but fever is usually low-grade or absent with *E. coli* O157:H7. Within 5–7 days of onset of illness, patients develop oliguria, pallor, irritability, and fatigue. Hypertension is also frequently present. Laboratory evaluation reveals hemolytic anemia with schistocytes present on peripheral smear, thrombocytopenia, and elevated blood urea nitrogen and creatinine. Treatment of HUS is supportive: careful fluid status monitoring and management, management of electrolyte derangements and metabolic acidosis associated with renal failure, antihypertensive medication, and dialysis if required. Although bloody stools may be seen in the setting of intussusception, renal failure, hemolytic anemia, and thrombocytopenia are not typically associated with intussusception, irritable bowel syndrome, or nephrolithiasis.

Question: 86

A 16-year-old boy developed acute respiratory distress syndrome (ARDS) in association with sepsis and required intubation and mechanical ventilation. Several days later, he developed tachycardia, hypoxemia, and hypotension. Auscultation of the chest reveals absent lung sounds on the left. On the basis of this information, the critical care nurse suspects that the patient has developed

- A. worsening ARDS.
- B. accidental extubation.
- C. tension pneumothorax.
- D. plugging of the endotracheal tube with pulmonary secretions

Answer: C

Explanation:

Asymmetric lung sounds in the setting of hemodynamic instability and hypoxemia is highly suggestive of tension pneumothorax. Because of the patchy nature of lung injury with acute respiratory distress syndrome (ARDS), there is often great variation in alveolar distention with mechanical ventilation, which can lead to air leaking into the pleural, mediastinal, pericardial, or subcutaneous spaces. Once air leakage begins, each subsequent ventilator-delivered breath results in additional air accumulation, which can ultimately progress to a tension pneumothorax. As the volume of air in the pleural space accumulates, the mediastinal structures are shifted away from the tension pneumothorax, and tracheal deviation may be evident. Cardiac output is diminished due to impaired venous return, leading to hypotension and compensatory tachycardia. Although accidental extubation or plugging of the endotracheal tube may lead to rapid respiratory and hemodynamic compromise in the critically ill patient, asymmetric breath sounds in this patient are more

consistent with a tension pneumothorax. The rapid change in this patient's status suggests an acute event rather than a general worsening of his underlying ARDS.

Question: 87

A 6-year-old child is brought in for evaluation after a minor head injury during recess at school. On arrival, he is awake and recognizes his mother, but he cannot recall the name of his school or his teacher. The cranial nerves are intact, and he can move all of his extremities. He is admitted to the general medical floor for observation. Six hours later, his mother attempts to wake him from a nap and is unable to do so. The nurse arrives to find him unresponsive with mid-sized, unresponsive pupils and irregular respirations. Painful stimuli elicit flexor (decorticate) posturing. What is the most likely explanation for this patient's deterioration?

- A. Infectious encephalitis
- B. Acute hypoglycemia due to poor oral intake
- C. Seizure
- D. Impending brain herniation

Answer: D

Explanation:

The patient described in the question is demonstrating signs of intracranial hypertension and brain herniation after a head injury and requires emergent intervention to avoid irreversible brain cell death. Herniated brain parenchyma is not well perfused and rapidly becomes ischemic. Detailed neurologic examination findings differ somewhat, depending on which portion of the brain is affected, but all patients with intracranial hypertension demonstrate altered mental status and decreased level of consciousness initially. Symptoms of progression include pupillary/cranial nerve abnormalities, vomiting, vital sign changes, posturing, and altered respiratory pattern. Management of elevated intracranial pressure should begin as soon as possible after recognition. Infectious encephalitis may present with altered mental status and herniation syndrome but would be an unlikely coincidence given the history of head injury in this patient. This patient would be unlikely to develop symptomatic hypoglycemia after an afternoon of poor oral intake, and pupillary changes with posturing would be less likely in the setting of hypoglycemia. Post-traumatic seizures occur in the setting of head injury without intracranial hypertension or brain herniation, but this patient's constellation of symptoms should be treated as brain herniation until proven otherwise.

Question: 88

A 12-year-old boy is hospitalized with altered mental status. His family reports that he has been ill for several days with fever, headache, and mouth sores. Over the last 2–3 days, he developed personality changes, lethargy, hallucinations, difficulty speaking, and weakness. Cerebrospinal fluid studies reveal mildly elevated protein, normal glucose, 200 red blood cells/mm³, and 700 white blood cells/mm³ (85% lymphocytes). Cerebral spinal fluid gram stain reveals no organisms. Magnetic resonance imaging of the brain is obtained and shows marked abnormalities in the temporal lobes. Which of the following organisms is the most likely cause of this patient's illness?

- A. Herpes simplex virus
- B. Streptococcus pneumoniae
- C. Rabies virus
- D. Salmonella typhi

Answer: A

Explanation:

The most common etiologic agent of meningoencephalitis in the United States is herpes simplex virus (HSV). Neonatal HSV encephalitis is most commonly caused by genital herpes (HSV-2) acquired during vaginal delivery. Encephalitis in older children and adults is most commonly caused by oral herpes (HSV-1). A prodrome of headache, fever, and malaise is followed shortly by behavioral or mental status changes, seizures, and focal neurologic abnormalities (e.g., weakness, aphasia, cranial nerve dysfunction). Magnetic resonance imaging generally demonstrates marked abnormalities in the temporal lobes. Although illness caused by Salmonella typhi (typhoid fever) can include neuropsychiatric symptoms, the short duration of this patient's illness before the onset of neurologic symptoms, the absence of gastrointestinal symptoms, and the lack of reported exposure or travel make typhoid fever less likely. Streptococcus pneumoniae would more likely lead to a classic bacterial meningitis than the aseptic meningoencephalitis described in this patient. Although rabies virus may cause dramatic and progressive neurologic symptoms after a febrile prodrome, brain imaging studies are generally normal.

Question: 89

The critical care nurse is taking care of a previously healthy 21-month-old child who has been hospitalized for vomiting and dehydration secondary to a presumed viral illness. His mother reports that the rest of the family has been ill with a "stomach virus" recently as well. Despite intravenous fluid resuscitation, the nurse notes that the child has not improved clinically. He continues to have intermittent crampy abdominal pain episodes that are followed by bilious vomiting, and he has grown progressively more listless over the course of the nurse's shift. Several hours into the shift, he passes a small amount of bloody mucus rectally. The most likely explanation for this patient's clinical deterioration is

- A. progression of an unrecognized bacterial enteritis.
- B. inadequate fluid administration.
- C. progression of an unrecognized intussusception.
- D. inadequate use of antiemetic medications.

Answer: C

Explanation:

This patient is exhibiting classic symptoms of ileocolic intussusception, a form of bowel obstruction in which part of the large intestine telescopes into a more distal portion of large bowel. Most commonly seen in the toddler age-group, intussusception presents with colicky intermittent episodes of severe abdominal pain lasting 1–3 minutes, often culminating in bilious vomiting. Initially, patients appear well between pain episodes but progress to worsening listlessness and lethargy as bowel ischemia worsens. The classic "currant-jelly stool" is often a late finding in intussusception. Untreated, intussusception is uniformly fatal. Abdominal x-

rays may reveal absence of air in the right lower quadrant, a soft tissue mass (the intussusceptum) usually in the right upper quadrant region, and an obstructive bowel gas pattern. Ultrasound of the abdomen reveals the intussusception as well. Diagnosis may be confirmed with air contrast enema, and of ileocolic intussusception can be successfully reduced during air contrast enema as well. Definitive treatment is operative.

Question: 90

The emergency department is at maximum patient capacity and is attempting to transfer a young boy to the critical care unit as soon as possible to use their limited staff most effectively. The most appropriate reason to delay transferring the patient to the critical care unit is which of the following?

- A. The critical care nurse who will take care of this patient is still on dinner break
- B. The patient has deteriorated and requires further stabilization before transfer
- C. The patient's mother is with the patient, but the father is still en route to the hospital
- D. The emergency room nurse is working past the end of her shift to care for this boy

Answer: B

Explanation:

Effective collaboration with other patient units and disciplines requires both awareness of and respect for the unique challenges and strengths of other patient care providers. Avoidance of receiving a patient in the critical care unit as a result of any factor other than providing the high-quality, safe medical care for the patient is inappropriate. So-called "turf wars" between disciplines or patient care units work directly against the collaborative model of care that is best for the patient. The critical care nurse should model a professional relationship with other members of the care team that encourages cooperation and respect between team members.

Question: 91

Which of the following quality improvement models would be most beneficial for employee satisfaction and patient safety outcomes?

- A. Quality improvement changes dictated solely by hospital administrators in response to poor outcomes and errors
- B. Identification of care providers committing the most serious errors so that they can receive further individualized training or termination
- C. Open, nonpunitive discussion of errors and serious events, leading to standardized and systematic problem-solving
- D. Private reviews of serious events so that changes can be made for that individual case

Answer: C

Explanation:

Quality improvement is a critical component of providing the best patient care and should be an

integral part of any patient-care institution or department. Often, a "trigger" event, such as A medical mistake that led to a poor outcome or new department leadership that prompts a quality improvement project. Ideally, the trigger event leads to a quality improvement process characterized by multidisciplinary teams of staff that can identify problems, evaluate potential solutions to the identified challenges and barriers, and implement new treatment/efficiency practices. resulting in improved outcomes. When staff members feel invested in the quality improvement process and mistakes or poor outcomes are evaluated in a nonjudgmental, nonpunitive fashion, patient safety and quality of care are improved, and staff feel adequately supported in their work environment.

Question: 92

A 6-year-old healthy child is admitted with an isolated lower extremity fracture sustained during a fall from his bicycle. He is receiving maintenance intravenous fluid and intravenous narcotic pain medication. The most appropriate way to monitor this patient's oxygenation is by

- A. pulse oximetry.
- B. the child's skin color.
- C. serial arterial blood gas measurement.
- D. continuous capnography monitoring.

Answer: A

Explanation:

There are several ways to monitor a patient's oxygenation, ranging from intermittent noninvasive to continuous invasive monitoring. The patient described in the question is receiving intravenous narcotics to treat pain associated with a fracture but is otherwise stable without reported cardiac or pulmonary disease. Intravenous narcotics can cause respiratory depression, even when given in appropriate doses at appropriate intervals. Since respiratory depression may range from mild hypopnea to a full respiratory arrest, patients receiving intravenous narcotics should be carefully monitored. Pulse oximetry is usually adequate in the otherwise healthy patient for following oxygenation status, while end-tidal CO₂ monitoring (capnography) is useful for following ventilation. Children generally do not appear clinically cyanotic until blood oxygen saturation is less than 85%; therefore, observing a child's skin color as the primary means of assessing oxygenation is inadequate. Invasive arterial oxygenation monitoring is not indicated in the hemodynamically stable healthy patient who is receiving intravenous pain medication in association with an uncomplicated fracture.

Question: 93

A pediatric onc010U patient tells the nurse that the odor of the alcohol-based sanitizer makes her feel extremely nauseated. Hospital policy states that staff members in contact with a patient need to either complete a thorough 30-second hand washing or use hand sanitizer before and after patient contact. Most staff members find they can perform their duties more efficiently with the use of hand sanitizer, which requires less time spent cleaning their hands. The nurse's best action in this case is to

- A. note the patient's preference in the chart, post a sign at the entrance to the patient's room, and request that caregivers wash their hands and not use hand sanitizer.
- B. treat the patient's nausea with an antiemetic medication as ordered by the physician.
- C. explain to the patient why staff members prefer to use hand sanitizer.
- D. minimize interactions with the patient so that she can have fewer exposures to the odor of hand sanitizer.

Answer: A

Explanation:

Flexibility and creativity are often the most helpful tools in the nurse's repertoire, particularly when the preferences of the patient or family conflicts with hospital policy or provider preference. In addition to assisting with the implementation of a straightforward, reasonable, and effective plan consistent with hospital policy, in this case (hand-washing), the nurse is problem-solving with the patient's unique needs and preferences in mind. Although it is not inappropriate to treat the patient's symptoms, it would be more effective in this case to minimize the patient's exposure to hand sanitizer whenever possible. Although it may be appropriate for the nurse to explain why many providers use hand sanitizer, it is important for him or her to advocate for the patient's preference as well.

Question: 94

The critical care nurse is taking care of a patient who is being monitored after cardiac catheterization. Complications that the critical care nurse expects include

- A. bleeding at the arterial puncture site.
- B. cerebrovascular accident.
- C. cardiac tamponade.
- D. renal failure.

Answer: A

Explanation:

Patients who have undergone cardiac catheterization are generally observed in the hospital for 12–24 hours to monitor for complications. Immediately after the procedure, pressure is applied to the site of arterial puncture until bleeding stops. Generally, the patient is kept still and flat for several hours, and the arterial puncture site is assessed regularly for bleeding, hematoma formation, pain, and palpable distal pulses. The most common complications After cardiac catheterization involve the site of the arterial puncture, such as bleeding, hematoma, and pseudoaneurysm formation. More serious complications during or after cardiac catheterization include cerebrovascular accident or myocardial infarction due to thrombi or hemorrhage in the cardiac or cerebral vessels, allergic reaction, cardiac tamponade, arrhythmia, and renal failure.

Question: 95

A patient with status asthmaticus is intubated for respiratory failure. Which of the following statements about mechanical ventilation of the asthmatic patient is true?

- A. Airway obstruction and air trapping leads to greater risk of barotrauma with mechanical ventilation

- B. Asthmatic patients benefit from shortened exhalation times on the ventilator
- C. Pulmonary air trapping leads to increased venous return to the heart and, therefore, increased cardiac output
- D. Asthmatic patients usually benefit from higher-than-normal ventilator respiratory rates

Answer: A

Explanation:

The pulmonary mechanics of status asthmaticus create significant challenges with regard to mechanical ventilation. Generally, intubation and mechanical ventilation are options of last resort to be used only when the patient is deteriorating despite maximal therapy. The degree of air trapping and airway obstruction in the severe asthmatic leads to a significantly higher incidence of barotrauma (e.g., air leak syndrome, pneumothorax) in the mechanically ventilated patient with asthma. To reduce the likelihood of barotrauma, asthmatic patients on mechanical ventilation are generally managed with what is referred to as "permissive hypercapnia," tolerating some degree of carbon dioxide retention to allow for reduced peak inspiratory pressures. Longer exhalation times and decreased respiratory rates reduce the risk of breath-stacking and worsening air-trapping. Significant air-trapping leads to impaired venous return to the right heart, which, in turn, leads to decreased cardiac output. As a result, these patients generally need intravenous fluid administration and close hemodynamic monitoring.

Question: 96

A colleague reports that their advanced life support credentialing has lapsed due to scheduling conflicts. He admits that he does not intend to renew until one of administrators notices that his credentials have expired as "no one really keeps track of this stuff." The critical care nurse's first step in this case is to

- A. report the lack of adequate nurse credentialing oversight to the hospital administration.
- B. remind the colleague that the credentialing requirements enhance patient safety and assist him in scheduling a renewal course as soon as possible,
- C. Leave the monitoring of staff compliance with credentialing requirements to the hospital administration.
- D. Lodge an anonymous complaint with the state nursing board about your colleague.

Answer: B

Explanation:

One of the most important responsibilities of the critical care nurse is to complete and maintain all required credentialing to provide the best patient care and to comply with the specific requirements of his or her employer. Additionally, the critical care nurse should model compliance with required certifications and assist or encourage colleagues to do so as well. Patient care is optimized when team members support each other in maintaining the skills necessary to care for the critically ill patient. If the first step as described above is ineffective, it would be appropriate for the nurse to confidentially notify the appropriate supervisor of the situation.

Question: 97

A patient with refractory septic shock has a pulmonary artery (PA) catheter placed for

hemodynamic monitoring. Which of the following statements is most accurate regarding PA catheter monitoring?

- A. It is unusual for the critical care nurse to be involved in monitoring the pulmonary artery catheter waveforms
- B. An acute pulmonary embolus would be expected to result in elevated systolic pulmonary artery pressures
- C. Cardiac tamponade would be expected to result in decreased pulmonary artery wedge pressure
- D. Vasopressor administration would not be expected to change most values measured by the pulmonary artery catheter

Answer: B

Explanation:

Pulmonary artery (PA) catheters allow for measurement of central venous pressure as well as PA systolic/diastolic pressures, mean PA pressure, and pulmonary artery wedge pressures (PAWPs), among other variables. The PA is a reflection of pulmonary vascular resistance and ventricular function. The PA systolic pressure reflects the pressure generated by the right ventricle during ejection of blood into the pulmonary circulation: it increases in conditions associated with increased pulmonary vascular resistance, such as pulmonary embolus or acute respiratory distress syndrome. The PA end-diastolic pressure is usually a reflection of left ventricular end-diastolic pressure and will increase in the setting of left ventricular dysfunction. Both PA systolic and end-diastolic pressure are decreased with hypovolemia. The PAWP is obtained with inflation of the balloon at the catheter tip and is a reflection of mean left atrial pressure. The PAWP is increased in the setting of left ventricular dysfunction, cardiac tamponade, and hypervolemia. The PAWP is decreased in the setting of hypovolemia and pulmonary embolism. The PA catheter placement is frequently indicated in the patient receiving vasopressors, as it allows for closer hemodynamic monitoring. The critical care nurse is intensely involved in monitoring PA catheter waveforms.

Question: 98

When caring for a patient with a subclavian central line catheter, the nurse should understand that which one of the following is correct regarding central line-associated blood infections (CLABSI)?

- A. The central line catheter should be changed every 14 days to prevent a CLABSI,
- B. The central line insertion site will be red and warm to the touch when a CLABSI is present.
- C. Risks for CLABSI increase as central-line-present days increase.
- D. Using BioPatches with central line dressings is the most effective way to prevent a CLABSI.

Answer: C

Explanation:

The length in days of central line presence correlates with increased CLABSI risk. It is not recommended to change central lines every 14 days. The best practice is to determine central line necessity daily and remove it when it is no longer needed. Central line insertion sites can appear to be within normal limits when CLABSI is present. Although using BioPatches is recommended to prevent CLABSI, shortening the time that the central line is present is the most effective preventive measure.

Question: 99

A developmentally normal adolescent patient with insulin-dependent diabetes mellitus is in the critical care unit for the fourth time in several weeks with diabetic ketoacidosis due to noncompliance with his insulin regimen. In this situation, which of the following actions is most appropriate?

- A. Tell the patient about another noncompliant child who died of diabetes
- B. Contact child protective services about placing the child in a home so he will be more closely monitored
- C. Advise the patient's family that they should take away the patient's privileges until he is compliant with his insulin
- D. Help arrange for the patient to attend a peer support group for diabetic adolescents

Answer: D

Explanation:

Noncompliance with treatment regimens in the setting of a chronic medical illness such as diabetes is common in the adolescent patient. Conflict between the patient and family may lead to poor communication and ongoing difficulties with compliance. Often, the adolescent patient is more receptive to health-related information and resources when it is presented by a medical provider with whom the patient has established rapport or by the adolescent's peer group. In this setting, the critical care nurse can be instrumental in assisting the adolescent patient in pursuing opportunities that contribute to healthy decision-making and information-seeking. Scare tactics and threats are rarely effective in changing behavior in the noncompliant adolescent patient.

Question: 100

The critical care nurse works in a critical care unit where physicians and nurses generally address each other by their first names in the professional environment. One of the new pediatric pulmonologists firmly insists that all staff members address him as "Doctor" to "show their respect." The nurse's best action in this situation is to

- A. address the physician by his first name so that he can become aware of the usual practice in this critical care unit.
- B. refer to him as "Doctor" in front of patients and families, but refer to him by his first name at all other times.
- C. Honor his request to be addressed as "Doctor" without changing your practice with respect to other colleagues in the unit.
- D. Insist that he refer to you by your professional title as a "sign of respect" so that he learns how it feels to be treated this way.

Answer: C

Explanation:

Interpersonal difficulty among staff members in any profession impairs the ability of staff to provide the best possible care for the patient. Although the conflict described in this case does not directly involve

patient care, a lack of respect between members of the care team virtually always ends up harming the patient in some way. The critical care nurse's commitment to the patient should be reflected not only in direct patient interactions but also in the nurse's professional relationships with colleagues. Resolving interpersonal difficulty while maintaining the dignity of all involved improves communication and accountability within the care team.

Question: 101

When caring for the pediatric patient with a brain tumor, which of the following actions by the critical care nurse is most appropriate?

- A. Minimize neurologic checks so that the patient can get more rest
- B. Clarify the patient's "code" status
- C. Minimize interventions that increase intracranial pressure
- D. Have the patient lie flat when asleep

Answer: C

Explanation:

Patients with a brain tumor need careful Attention to their neurologic status both preoperatively and postoperatively to detect changes in neurologic status early and maximize neurologic function. In addition to monitoring the airway, breathing, hemodynamics, and patient comfort. the critical care nurse should monitor the patient's neurologic status frequently. This includes examination of the patient's mental status, pupils, and general motor and sensory function. The head of the patient's bed is generally kept up around 30 degrees, including during sleep. to minimize brain edema by enhancing venous drainage. Interventions that are known to increase intracranial pressure (e.g., painful procedures, endotracheal tube suctioning) are minimized to the extent possible to avoid spikes upward in intracranial pressure. Although it is important to be aware of and clarify the patient's "code status" in the event of a rapid deterioration, direct patient care is prioritized in most circumstances.

Question: 102

A 14-month-old child with bronchopulmonary dysplasia secondary to prematurity is admitted to the critical care unit with respiratory syncytial virus (RSV) bronchiolitis. Which of the following statements about this patient is most accurate?

- A. The patient's daily maintenance pulmonary medications should be withheld during treatment of acute RSV
- B. Infants with bronchopulmonary dysplasia have an increased risk of serious pulmonary infections into early childhood
- C. Surfactant administration would likely improve pulmonary compliance in this patient
- D. Bronchopulmonary dysplasia does not increase the risk of serious pulmonary complications after 1 year of age

Answer: B

Explanation:

Bronchopulmonary dysplasia (BPD, or chronic lung disease) is characterized by the development of

chronic pulmonary damage likely as a result of disruption in both alveolar and pulmonary vasculature in premature infants requiring prolonged oxygen therapy and positive-pressure ventilation in the neonatal period. Risk of BPD is highest in infants born at younger gestational ages or with low birth weights. Infants with BPD are at risk for severe complications of acute pulmonary infections and obstructive pulmonary disease well after the neonatal period. Poor growth and developmental delay are also common. Maintenance medications (e.g., bronchodilators, diuretics, fortified enteral feedings) should be continued whenever possible in the setting of acute illness. Although surfactant administration is indicated in the treatment of neonatal respiratory distress syndrome, there is generally no clinical benefit with surfactant use beyond the immediate neonatal period in BPD.

Question: 103

A 10-year-old girl remains sedated after resection of a pituitary tumor 24 hours ago. She develops increasing urine output, tachycardia, and worsening peripheral perfusion. Laboratory results include serum sodium, 150 mmol/L; urine osmolality, 160 mOsm/kg; urine specific gravity, 1.002; and serum osmolality, 325 mOsm/kg. The most likely explanation for these findings is

- A. excessive sodium administration in the postoperative period.
- B. diabetes insipidus.
- C. diabetes mellitus.
- D. chronic renal disease, complicating the postoperative course.

Answer: B

Explanation:

Diabetes insipidus (DI) is characterized by inappropriate water loss secondary to either inadequate antidiuretic hormone (ADH) production (central DI) or renal resistance to ADH effects (nephrogenic DI). Patients with DI have large volumes of inappropriately dilute urine with low urine osmolality, elevated serum osmolality, and hypernatremia. Central DI is a common complication after neurosurgery, particularly in cases involving the pituitary gland, where ADH is produced. Neurosurgical patients need to have urine output, serum electrolytes, urine and serum osmolality, and overall fluid balance followed closely in the postoperative period to ensure early recognition of m. If not promptly treated, patients with DI develop worsening hypernatremic dehydration, ultimately leading to cardiovascular collapse. Central DI is treated with slow correction of hypernatremia, fluid resuscitation, and ADH (vasopressin/desmopressin) replacement. Conscious patients with unlimited access to water will increase their oral fluid intake appropriately.

Question: 104

A 7-year-old boy with hemoglobin SS-variant sickle cell disease is hospitalized with status asthmaticus and is receiving high-dose nebulized bronchodilators and intravenous corticosteroids. His mother rushes out of his room and tells the nurse that "something is wrong with my son." Assessment reveals an alert patient who seems to be complaining of headache, although his speech is difficult to understand. Heart rate is 150 beats/min, respiratory rate is 36 breaths/min, and oxygen saturation is 94% on room air. When the patient's mother asks him to hold her hand, he seems unable to lift his right arm. The most likely cause of this patient's

symptoms is

- A. acute cerebrovascular accident.
- B. acute chest syndrome.
- C. migraine headache.
- D. corticosteroid side effect.

Answer: A

Explanation:

Acute cerebrovascular accidents (strokes) are one of the most serious complications of sickle cell disease and occur in up to 10% of patients. Some strokes in the sickle cell patient will be so-called "silent infarcts": that is, radiologic abnormalities consistent with infarct without a history of clinical symptoms. Symptomatic cerebrovascular accidents may present with headache, altered mental status, speech difficulty, weakness, ataxia, sensory changes, or seizures. This patient's focal neurologic dysfunction is consistent with a left-sided cerebrovascular accident. Regular screening of pediatric sickle cell patients with transcranial Doppler studies helps in identifying those sickle cell patients at highest risk of stroke. Prophylactic transfusions in high-risk patients appear to decrease the incidence of stroke in high-risk sickle cell patients. Acute chest syndrome and steroid side effects do not usually present with focal neurologic symptoms. Complex migraine headache may present with focal neurologic findings, which may mimic an acute stroke, but given this patient's sickle cell disease, acute stroke is more likely.

Question: 105

The primary mechanism of hypotension with anaphylaxis is

- A. inappropriate peripheral vasodilation.
- B. deficiency of intravascular fluid volume.
- C. obstruction of normal cardiac output.
- D. increased vagal tone.

Answer: A

Explanation:

Anaphylaxis describes a systemic inflammatory reaction to an inciting Allergen and may be associated with significant hemodynamic compromise and hypotension. Anaphylactic shock is a type of distributive shock, which is characterized by massive, inappropriate peripheral vasodilation caused by histamine release. This leads to venous pooling, impaired critical organ perfusion, and hypotension with a functional intravascular hypovolemia despite no whole-body fluid losses. Cardiac output is increased initially in distributive shock in response to the drop in systemic vascular resistance. Other causes of distributive shock include neurogenic shock associated with spinal cord injury, sepsis, and adrenal insufficiency crisis.

Question: 106

A 3-year-old boy presents with severe dehydration secondary to gastroenteritis. Physical examination reveals a lethargic, poorly perfused child with the following vital signs:

Heart rate: 175 beats/min

Respiratory rate: 40 breaths/min with good respiratory effort

Blood pressure: 70/30 mmHg

Oxygen saturation: 97% on room air

In this situation, the critical care nurse expects which of the following initial interventions?

- A. Intubation
- B. Initiation of intravenous vasopressor medication
- C. Rapid intravenous administration of 20 mL/kg of isotonic crystalloid solution
- D. Emergent O-negative red blood cell transfusion

Answer: C

Explanation:

This patient's clinical presentation is consistent with hypovolemic shock secondary to infectious gastroenteritis. The primary derangement in hypovolemic dehydration and shock is inadequate intravascular volume. Treatment (after assessment and stabilization of the patient's respiratory status) is intravascular volume replacement. Initial fluid of choice in pediatric hypovolemic shock is intravenous crystalloid (e.g., normal saline) administered in boluses of 20 mL/kg over 10–20 minutes. Often, the patient presenting in shock requires at least 60 mL/kg of intravenous crystalloid administration during initial fluid resuscitation. Although this patient may ultimately require endotracheal intubation and mechanical ventilation, he is currently maintaining adequate oxygenation with good respiratory effort. Vasopressor medications are not indicated in the management of hypovolemic shock unless the patient has been given adequate fluid replacement therapy and has persistent refractory shock. Blood transfusion is not the initial treatment of choice in most cases of pediatric hypovolemic shock but may be indicated after 60–80 mL/kg crystalloid solution has been administered.

Question: 107

In which of the following situations would the critical care nurse expect heliox therapy (inhaled helium—oxygen mixture) to be included in the treatment plan?

- A. Bacterial pneumonia
- B. Croup
- C. Tricyclic antidepressant overdose
- D. Acute chest syndrome

Answer: B

Explanation:

Heliox is a mixture of helium and oxygen gases, which flow less turbulently through the airways than oxygen or nitrogen due to the improved laminar flow that results from helium's low density. The resultant decrease in force required to move the inhaled gas through the airways results in decreased airway resistance and work of breathing. Heliox is used primarily in clinical situations involving upper or lower airway obstruction, such as croup, asthma, and bronchiolitis. The therapeutic benefit of heliox depends on the low density of helium gas; mixtures of less than helium are too dense, so only patients requiring less

than supplemental oxygen may benefit from heliox administration. Heliox can be administered to both intubated and non-intubated patients. Although there are no specific contraindications for heliox, tricyclic antidepressant overdose is not generally characterized by airway obstruction and is, therefore, an unlikely clinical scenario in which heliox would be used. Patients with bacterial pneumonia or acute chest syndrome may benefit from heliox administration if the clinical picture includes airway obstruction, but heliox is more likely in the setting of croup.

Question: 108

The nursing staff is developing a policy for teaching families to care for indwelling central intravenous catheters after discharge. Which of the following is the most effective way to accomplish this?

- A. Each nurse teaches family members about catheter care in their own way
- B. A standardized practice for discharge teaching, involving both written materials and face-to-face teaching with demonstration, is developed
- C. Families are given a written handout with instructions to read and asked if they have any questions About it before discharge
- D. The physician who placed the catheter explains home care to each family before discharge

Answer: B

Explanation:

Effective and consistent patient or family teaching is enhanced when interdisciplinary recommendations are evaluated and synthesized into a clear and consistent educational plan that can be used by staff, patients, and families. A combination of face-to-face teaching (with regard to specific device care or medical procedures) with clearly written and illustrated materials, which can serve as reference material for the family, improves the knowledge and skills of patients and family both in the acute care setting and after discharge. Standardizing recommendations and teaching methods decreases the risk that families will receive contradictory information.

Question: 109

In which of the following clinical scenarios would the critical care nurse most likely be asked to administer intravenous mannitol?

- A. Acute necrotizing pancreatitis
- B. Blunt head trauma
- C. Hypernatremic dehydration
- D. Acute adrenal insufficiency

Answer: B

Explanation:

Mannitol is an osmotic diuretic that is most commonly given to the pediatric patient in the setting of intracranial hypertension. Mannitol cannot cross the blood—brain barrier, resulting in movement of water out of brain cells into the extracellular space, leading to decreased brain edema. Mannitol is given intravenously in

doses of 1—2 mg/kg for intracranial hypertension. Mannitol may also be used to prevent and treat oliguric renal failure and intraocular hypertension or to enhance renal excretion after a toxic ingestion. Mannitol administration is not indicated in the patient with pancreatitis, hypernatremic dehydration, or adrenal insufficiency.

Question: 110

A critical care patient with air-leak syndrome is placed on a high-frequency oscillatory ventilator. Which of the following statements about high-frequency ventilation is most accurate?

- A. Oxygenation is primarily determined by the respiratory rate (frequency measured in Hz) with high-frequency ventilation
- B. High-frequency ventilation is associated with more barotrauma than conventional mechanical ventilation
- C. Accidental extubation is less likely with high-frequency ventilation
- D. High-frequency ventilation combines extremely small tidal volumes with high respiratory rates

Answer: D

Explanation:

High-frequency ventilation is a nonconventional form of mechanical ventilation that is indicated in patients with significant barotrauma (air-leak syndromes) or patients failing maximal mechanical ventilation. High-frequency ventilation uses small tidal volumes with high respiratory rates (frequency) to improve oxygenation and minimize barotrauma. The patient's oxygenation is affected by changes in the FiO₂ and mean airway pressure. Mean airway pressure is similar to continuous positive airway pressure on a conventional ventilator and maintains distension and recruitment of airways to avoid alveolar collapse. Ventilation is affected primarily by changes in amplitude (variation around the mean airway pressure) and to a lesser degree, frequency (respiratory rate). Because of the rapidly vibrating endotracheal tubing and patient, accidental extubation is more common with high-frequency ventilation than with conventional ventilation.

Question: 111

The critical care nurse is caring for a patient with a serious medical illness who is improving in the critical care unit. The patient's family informs her that they believe in alternative medical treatments, and they ask if there are any nontraditional therapies that could be added to their child's care. The nurse is aware of a new alternative medicine consult team in the hospital but has heard that the patient's attending physician is not a proponent of nontraditional medical care. In this situation, which of the following actions by the nurse would be most appropriate?

- A. Inform the primary medical team of this family's interest in alternative medicine, and remind them of the new alternative medicine consult service
- B. Tell the family that they need to choose between traditional and nontraditional medical care, but they cannot do both
- C. Tell the family that the medical team does not believe in alternative medical therapies
- D. Consult the alternative medicine team on behalf of the family without informing the primary medical team

Answer: A

Explanation:

The responsibility of the critical care nurse in this case involves advocating for the preferences of the patient or family, respecting the family's unique beliefs, and modeling responsiveness to a family's needs even when the clinician may have different beliefs. Communication, compliance with treatment, and overall family comfort with the care being provided is enhanced when the family's values and beliefs are incorporated into the patient's medical care whenever possible. Although consulting the Alternative medicine team on the family's behalf without informing the primary team may appear to be a less confrontational solution, future communication between the nurse and physician will be harmed by avoidance of a direct discussion of the issue.

Question: 112

Which of the following statements regarding patients with acute head injury is most accurate?

- A. The patient's cervical spine should remain immobilized during endotracheal intubation
- B. Head trauma patients should not be given sedative medication for endotracheal intubation
- C. Moderate systemic hypertension after head trauma should be treated aggressively
- D. Continuous cardiac monitoring is generally not required with head trauma patients

Answer: A

Explanation:

Management of the patient with traumatic brain injury requires close attention to multiple systems to maximize neurologic recovery. Establishing a safe airway is paramount, and immobilization of the cervical spine should be continued throughout airway management maneuvers whenever possible. Adequate patient sedation for painful procedures (e.g., intubation) that may increase intracranial pressure is also indicated. Lidocaine may be administered before intubation to further protect against an acute elevation in intracranial pressure. Close hemodynamic monitoring is required in the patient with brain injury to minimize dramatic fluctuations in cerebral perfusion. Systemic hypotension should be treated aggressively and hypertension should be managed thoughtfully to avoid a rapid fall in blood pressure (and cerebral perfusion).

Question: 113

A 9-year-old child is admitted to the critical care unit for observation after smoke inhalation secondary to a house fire. Initial assessment reveals an awake, patient with a hoarse voice and audible inspiratory stridor who appears anxious. Respiratory rate is 40 breaths/min, and oxygen saturation is 97% on room air. Given this information, which of the following interventions is most appropriate?

- A. Racemic epinephrine and corticosteroids
- B. Portable chest x-ray
- C. Intubation
- D. Anxiolytic medication

Answer: C

Explanation:

Smoke inhalation is a common cause of morbidity and mortality in injury as a result of fire. The patient described in the question is demonstrating signs of upper airway obstruction: anxiety, hoarseness, tachypnea, and stridor. In the setting of a smoke inhalation injury, these are indications for emergently securing the airway with endotracheal intubation regardless of oxygenation and ventilation parameters. The airway edema in smoke inhalation can cause rapid decompensation, leading to complete upper airway obstruction. It is important to remember that carbon monoxide exposure in the setting of fire-related smoke inhalation may lead to falsely reassuring pulse oximetry readings. High-flow supplemental oxygen should be administered to all patients with suspected smoke inhalation injury regardless of normal pulse oximetry to hasten the clearance of carbon monoxide.

Question: 114

The critical care nurse is taking care of a critically ill patient with a pulmonary artery catheter, which allows for SvO₂ (mixed venous oxygen saturation) monitoring. A decrease in SvO₂ well below normal is a reflection of which of the following?

- A. Decreased tissue oxygen demand relative to oxygen supply
- B. More effective cardiac output
- C. Excessive tissue oxygen demand relative to oxygen supply
- D. Patient agitation

Answer: C

Explanation:

Systemic mixed venous oxygen saturation (SvO₂) is a reflection of the balance between a patient's whole-body oxygen supply and demand. Normal SvO₂ is about 75%, meaning that normally body tissues extract about 25% of the oxygen that is delivered. A fall in SvO₂ reflects either decreased oxygen supply (i.e., decreased cardiac output, hypoxia) or increased oxygen demand, which exceeds the available supply (i.e., physiologic stress, pain, fever). The magnitude of the fall in SvO₂ indicates the degree of metabolic stress. Increased SvO₂ is a reflection of increased oxygen supply (i.e., increased cardiac output, increased oxygen-carrying capacity) or decreased oxygen demand relative to supply (i.e., hypothermia, sedation).

Question: 115

The critical care nurse is taking care of a 9-year-old patient with acute glomerulonephritis. The patient develops progressively worsening headache and shortness of breath. Vital signs reveal temperature 37.3 °C (99.1 °F); pulse, 115 beats/min; respiratory rate, 36 breaths/min; and blood pressure, 160/110 mmHg. Appropriate management of this patient consists of

- A. urgent administration of ordered pain relief medication.
- B. urgent administration of antihypertensive medication.
- C. initiation of intravenous dopamine to enhance renal perfusion.
- D. intravenous steroid administration.

Answer: B

Explanation:

The clinical presentation of the patient described in the question is consistent with a hypertensive crisis, characterized by systemic hypertension with evidence of acute or impending end-organ compromise (i.e., headache, shortness of breath). Symptoms of hypertensive emergency include severe headache, mental status changes, intracranial hemorrhage, cardiac ischemia, pulmonary edema, and acute renal failure. Most cases of hypertension in the pediatric population are due to renal disease (e.g., glomerulonephritis) or aortic coarctation. Management is aimed at careful reduction of blood pressure, using antihypertensive medication with the goal of avoiding a rapid or dramatic decrease in blood pressure to avoid impaired end-organ perfusion due to relative hypotension. Intravenous, short-acting, continuously infused antihypertensive medication in association with continuous invasive blood pressure monitoring is the most effective way to accomplish this. The choice of antihypertensive medication depends on the underlying etiology and consideration of the patient's specific cardiac and hemodynamic physiology. Examples include sodium nitroprusside, beta-blockers, and hydralazine.

Question: 116

A school-age patient who has been in the critical care unit for several weeks is receiving in-hospital tutoring to avoid falling too far behind in schoolwork during a prolonged hospitalization. The hospital tutor's teaching schedule conflicts directly with the patient's daily routine blood draw. The best way to remedy this situation is to

- A. collaborate with the tutor to arrange the schedule so that necessary medical care can be completed without interruption of the teaching session.
- B. ask the tutor to shorten the teaching sessions so that they no longer interfere with the patient's medical care.
- C. interrupt the teaching session to perform the blood draw at the usual time.
- D. encourage the family to place their child's medical care priorities above their child's educational goals.

Answer: A

Explanation:

Although the critical care patient's primary medical needs should be prioritized in virtually all situations, it is important for the nurse to work collaboratively with other disciplines, including nonessential services, such as education in this case, so that the patient can benefit from all of the resources and care available. A closed-minded focus on essential medical care, particularly in a stable patient, may result in the inability or unwillingness of the critical care nurse to use so-called "nonessential" resources that may benefit the patient.

Question: 117

The critical care nurse is taking care of a 6-year-old patient who has begun chemotherapy for a newly diagnosed malignant mediastinal mass. His serum potassium has risen from 4.0 mEq/L to 7.0 mEq/L in the last 12 hours. An electrocardiogram (EKG) is ordered. Which of the following EKG changes is expected first with hyperkalemia?

- A. Loss of the P wave
- B. Peaked T waves

- C. Sine wave pattern
- D. QRS widening

Answer: B

Explanation:

Hyperkalemia leads to sequential, predictable changes in the electrocardiogram (EKG), which hopefully allow for early recognition and treatment before the patient develops a life-threatening arrhythmia. The first abnormality seen on the EKG with hyperkalemia is peaked T waves. There may also be S-T segment depression and shortening of the QT interval in the early stages. As the serum potassium rises, the EKG will demonstrate prolongation of the P-R interval followed by widening of the QRS complex and disappearance of the P wave (Cie sine wave pattern). This is followed by ventricular tachycardia, ventricular fibrillation, or asystole.

Question: 118

A 3-year-old child is brought to the critical care unit after accidental near-strangulation with a window blind cord at home. The child responded well to early resuscitation at the scene and is alert without any signs of distress on initial arrival. Forty-five minutes after the initial event, the patient develops agitation, tachypnea, respiratory distress, and hypoxi

- a. The child is emergently intubated, and frothy, pink secretions are seen on direct laryngoscopy during intubation. Given this clinical scenario, the critical care nurse suspects that the patient has developed
- A. anaphylaxis.
 - B. elevated intracranial pressure secondary to hypoxic injury.
 - C. congestive heart failure.
 - D. post-obstructive pulmonary edema.

Answer: D

Explanation:

Post-obstructive pulmonary edema may develop acutely in a patient who previously appeared well and occurs in main clinical settings: after an episode of acute severe airway obstruction (type I) or after surgical relief of chronic airway obstruction (type II). Symptoms typically occur soon after the acute obstruction (or surgical procedure), often within 1—2 hours of the inciting event. The patient develops signs of significant respiratory distress, agitation, tachypnea, hypoxia, and rales. Treatment is supportive: patients usually require intubation, mechanical ventilation, supplemental oxygen, and occasionally diuretic administration. The etiology of post-obstructive pulmonary edema after a severe airway obstruction event is thought to be pulmonary capillary leak due to the large negative intrathoracic pressures generated when the patient is trying to inhale against an obstruction.

Question: 119

Which of the following statements about shock is most accurate?

- A. Patients with early septic shock may have warm peripheral skin and bounding pulses

- B. Packed red blood cell transfusion is the initial treatment of choice in most cases of pediatric hypovolemic shock
- C. Patients with isolated cardiogenic shock usually have decreased central venous pressure
- D. Distributive shock (e.g., anaphylaxis) is generally caused by vasoconstriction

Answer: A

Explanation:

Shock is defined as inadequate delivery of oxygen and nutrients to meet end-organ metabolic demands. The most common form of shock in the pediatric population is hypovolemic, usually as a result of dehydration in association with infectious illness. Hypovolemic shock may also occur in the setting of acute blood loss or conditions with loss of intravascular volume into interstitial tissues (e.g., burns, nephrotic syndrome). Crystalloid intravenous fluid Administration is the initial treatment of choice in most cases of pediatric hypovolemic shock, including hemorrhagic shock. Distributive shock is characterized by inappropriate systemic vasodilation and is typically seen in the setting of anaphylaxis, sepsis, and spinal cord injury. Cardiogenic shock is characterized by impaired cardiac pump function and resultant decreased cardiac output. Etiologies in the pediatric population include myocarditis, tamponade, sepsis, toxins, and congenital heart disease. Cardiogenic shock is associated with elevated central venous pressure. Septic shock often has a component of multiple types of shock, including distributive (secondary to massive vasodilation), hypovolemic (secondary to capillary leak), and cardiogenic. Signs of early septic shock are primarily associated with distributive shock: that is, peripheral vasodilation with compensatory increase in cardiac output, resulting clinically in warm, briskly perfused extremities, widening of the pulse pressure, and bounding pulses.

Question: 120

The critical care nurse is caring for a patient in the critical care unit whose family unit consists of the patient and his two mothers (i.e., a same-sex couple), one of whom is the patient's biological mother. The best way to communicate with this family is to

- A. find out which mother is his biological mother and communicate only with her.
- B. address both mothers as you would with a patient with opposite-gender parents.
- C. allow for visits by both mothers, but ask the nonbiological mother to leave when medical issues are being discussed.
- D. ask the unit social worker to evaluate the family to ensure that the child is being cared for appropriately because this is a nontraditional family.

Answer: B

Explanation:

Each individual patient and family brings their unique family circumstances, strengths, and challenges to the therapeutic relationship. Effective patient care, communication, and compliance with treatment is often impaired if a patient or family is not addressed with respect and consideration for their unique family dynamics and values. A child's parents should be treated with respect and compassion, regardless of gender, religion, culture, education, and income level. Children thrive in a variety of family settings, including those with same-sex parents. Considerations of whether each parent may consent for medical care may be addressed if necessary, just as they would be in any other family.

Question: 121

A 4-month-old boy with congenital hydrocephalus returns to the critical care unit after placement of a ventriculoperitoneal shunt. During a routine wound check, the nurse notices clear fluid draining from the scalp incision. Which of the following actions by the nurse is most appropriate in this situation?

- A. Place a new sterile dressing over the incision, and notify the neurosurgeon immediately
- B. Place a new sterile dressing over the incision, and notify the neurosurgeon if the fluid becomes bloody or cloudy
- C. Record the estimated volume of fluid drainage so that it can be factored into the patient's overall fluid balance
- D. Leave the incision site open so the wound can be monitored more closely

Answer: A

Explanation:

Clear drainage from the incision after placement of a ventriculoperitoneal shunt is assumed to be cerebrospinal fluid until proven otherwise. Prompt notification of the neurosurgeon after covering the wound with a sterile dressing to avoid further contamination is the most appropriate action in this case. Waiting for the fluid to become bloody or cloudy puts the patient at risk of developing shunt-related meningitis. Leaving the wound exposed without a sterile dressing increases the risk of contamination. Although strict monitoring of fluid intake and output is generally indicated in the critically ill patient, further action needs to be taken in this case.

Question: 122

A 4-year-old child hospitalized for status asthmaticus is treated with continuous nebulized bronchodilators, supplemental oxygen, intravenous corticosteroids, and intravenous magnesium sulfate. Four hours after admission, assessment reveals a somnolent child who is difficult to arouse. Respiratory rate has decreased from 40 breaths/min to 18 breaths/min. Auscultation of the chest reveals inspiratory and expiratory wheezes throughout with markedly decreased aeration. The next appropriate action by the critical care nurse is to

- A. continue to monitor the patient for further improvement.
- B. alert the physician of a change in status and prepare for intubation.
- C. try the patient on intermittent bronchodilator treatments.
- D. administer an intravenous crystalloid bolus to treat the child's dehydration.

Answer: B

Explanation:

The patient described in the question is demonstrating signs of impending respiratory failure: decreased level of consciousness and a marked drop in respiratory rate. Arterial blood gas obtained in this patient would likely demonstrate an elevated PCO₂ consistent with respiratory fatigue. Despite aggressive asthma therapy, this patient has deteriorated significantly and requires urgent ventilatory assistance. Indications for intubation in the patient with acute asthma include decreased mental status, inability to

maintain adequate oxygenation, and impending respiratory failure. The drop in this patient's respiratory rate is an ominous sign of impending respiratory failure, rather than improvement, given the patient's deteriorating mental status and worsening lung examination. Further observation and a decrease in bronchodilator dosing would only hasten this patient's deterioration. Although patients with status asthmaticus often require intravenous fluid administration to maintain adequate intravascular volume, this patient's impending respiratory failure needs to be attended to first.

Question: 123

A 2-year-old boy with congenital heart block has been admitted to the intensive care unit after having a cardiac pacemaker placed. Soon afterward, he develops agitation and respiratory distress. Examination reveals tachycardia, tachypnea, hypotension, equal clear breath sounds, neck vein distention, and diminished heart sounds. On the basis of this information, the nurse suspects that the patient has most likely developed

- A. pulmonary embolus.
- B. cardiac tamponade.
- C. acute myocardial infarction.
- D. tension pneumothorax

Answer: B

Explanation:

Cardiac tamponade is a potentially life-threatening accumulation of fluid in the pericardial sac, which leads to impaired ventricular filling during diastole. Cardiac tamponade may be a complication of cardiac instrumentation or open-heart surgery. It is also associated with penetrating chest trauma, infectious or autoimmune pericarditis, malignancy, central line placement, and renal failure. The patient described in the question had three signs of acute-onset cardiac tamponade referred to as Beck's triad: jugular venous distention (secondary to impaired venous return), hypotension (secondary to reduced stroke volume), and diminished heart sounds (secondary to the fluid-filled pericardial sac). Tamponade may also cause hepatomegaly, pulsus paradoxus, and altered mental status. Treatment includes supplemental oxygen, intravenous fluid administration, inotropic support, and drainage of the excessive pericardial fluid with pericardiocentesis. Neck vein distention and diminished heart sounds are not classically associated with pulmonary embolus. Acute myocardial infarction may present similarly but is less likely in this patient than acute cardiac tamponade. Tension pneumothorax is a possible complication after pacemaker placement although the clear equal breath sounds described in the patient make tension pneumothorax less likely.

Question: 124

The critical care unit has just implemented a new patient restraint policy after reviewing the relevant clinical recommendations. One of the nurses remarks that she has no interest in adhering to the new recommendations because her way "has been working just fine for years." The best response to this nurse's comments is to

- A. submit an official complaint about her to the nursing administration.
- B. recommend that she continue with her usual practice since it has worked well.

- C. implement the new policy without being concerned with what colleagues are doing.
- D. encourage the nurse to discuss her concerns with her supervisors.

Answer: D

Explanation:

Changes in policy or procedures in the patient care setting are often initially met with resistance from staff members, primarily due to the natural discomfort that comes with the learning curve of trying something new. Effective changes in practice depend on a transparent and collaborative process, which elicits the experience and feedback of staff members who will be asked to change their practice. Clear explanation of how and why a particular policy change is being put into effect is helpful in obtaining cooperation from staff. Even when the process has been collaborative and transparent, resistance to changing practice is an expected response. It is important for the critical care nurse to encourage nurse colleagues to remain open-minded about care changes and to model participation in establishing improved patient care practices.

Question: 125

Hospital policy states that all patients and families must be screened for psychosocial assistance needs before discharge. Nursing staff notes that the daytime social workers are overwhelmed with day-of-discharge evaluation requests, and as a result, many patients who are medically ready to be discharged remain in the hospital for an additional 2—24 hours awaiting social work evaluation. In this situation, it is most effective for the staff to

- A. encourage the hiring of additional daytime social workers despite widespread hospital budget reductions.
- B. encourage the social workers to work more quickly.
- C. encourage a hospital-wide policy change to place more emphasis on medical care and less emphasis on psychosocial support.
- D. attempt to use other available resources (e.g., night-shift social workers) to evaluate patients and families earlier in the hospital stay to avoid delays in discharge.

Answer: D

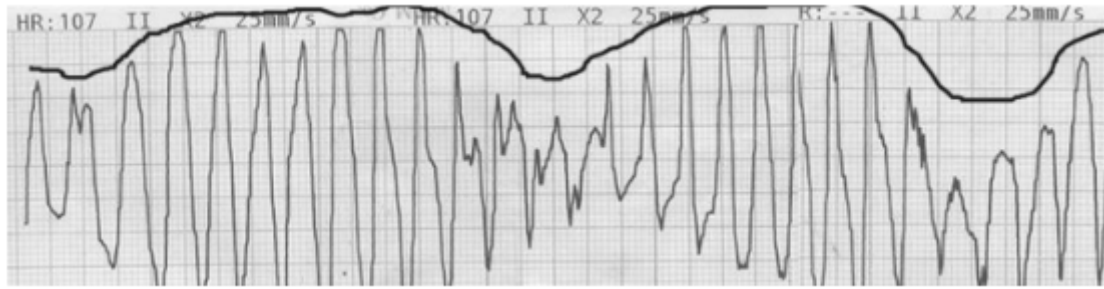
Explanation:

Nurses are often situated uniquely to identify both challenges and potential solutions to inefficiencies and patient safety challenges. This case demonstrates the collision of an important organizational goal (i.e., screening for psychosocial needs) with the need to discharge patients promptly. Rather than dismissing an important organizational goal (i.e., urging less emphasis on social support), straining hospital resources in a time of spending cuts (i.e., hiring more social workers), or attempting to urge particular staff members to work harder, the creative and more effective solution depends on both awareness and efficient use of available Alternative resources.

Question: 126

A 14-year-old boy in the critical care unit after drainage of a peritonsillar abscess is recovering. He is being treated with intravenous clindamycin. The preoperative electrocardiogram (EKG) is remarkable for a corrected QT interval of 520 msec. Family history

reveals that several family members died suddenly without explanation in their twenties and thirties. The patient complains of dizziness and palpitations and within seconds loses consciousness. The EKG is below.



After emergent cardioversion or defibrillation, which of the following medications should be administered next?

- A. Diphenhydramine
- B. Terbutaline
- C. Magnesium sulfate
- D. Norepinephrine

Answer: C

Explanation:

The electrocardiogram (EKG) that accompanies the question demonstrates a specific form of polymorphic ventricular tachycardia called torsades de pointes, which occurs in the setting of an underlying prolonged QTc interval. The QRS axis appears to "twist" around the baseline in torsades de pointes. This form of ventricular tachycardia is often brief and self-limiting but can degenerate to ventricular fibrillation. Treatment acutely consists of defibrillation/cardioversion as needed and intravenous administration of magnesium sulfate. Magnesium is the treatment of choice for terminating persistent torsades arrhythmia. Transvenous atrial pacing may also be effective. Prolonged QTc interval may be congenital (as is likely in this patient's case) or acquired. There are numerous causes of acquired prolonged QTc, including medication effect, electrolyte abnormalities (e.g., hypokalemia, hypocalcemia), starvation, central nervous system disease, and endocrinopathies. Patients with underlying prolongation of the QTc interval are at increased risk for arrhythmia in the setting of other factors, which prolong QTc, such as electrolyte abnormalities or the administration of medications known to prolong the QT interval.

Question: 127

A 12-year-old girl with bacterial meningitis develops worsening headache, hypertension, bradycardia, irregular respirations, and markedly decreased level of consciousness consistent with elevated intracranial pressure and impending brain herniation. Which of the following interventions is anticipated in the management of this patient after evaluation and stabilization of the patient's airway and circulatory status?

- A. Fluid restriction to maintain blood pressure lower than normal
- B. Placement of the patient in the Trendelenburg position
- C. Mild hyperventilation with goal PACO₂ around 35 mmHg

D. Intravenous ketamine administration

Answer: C

Explanation:

In managing the patient with intracranial hypertension, the patient's head should be elevated to about 30 degrees to enhance cerebral venous drainage. Hypercapnia causes cerebral vasodilation, which exacerbates intracranial hypertension, but overly aggressive hyperventilation leads to a harmful decrease in cerebral blood flow. Therefore, mild hyperventilation with a goal PACO₂ in the mid-30s is ideal with initial medical management of intracranial hypertension. Maintenance of normal intravascular volume and prompt treatment of systemic hypotension is important to maintain adequate cerebral perfusion, particularly in the patient with elevated intracranial pressure. Ketamine administration is contraindicated in the patient with elevated intracranial pressure.

Question: 128

Which of the following statements most accurately describes obstructive hypertrophic cardiomyopathy?

- A. Hypertrophic cardiomyopathy rarely leads to sudden death
- B. Symptoms of hypertrophic cardiomyopathy are more pronounced during rest than with exertion
- C. Patients with hypertrophic cardiomyopathy have more symptoms when they are dehydrated
- D. Dyspnea and syncope are common presenting symptoms of hypertrophic cardiomyopathy

Answer: D

Explanation:

Obstructive hypertrophic cardiomyopathy, or idiopathic hypertrophic subaortic stenosis, is usually characterized by enlargement of the interventricular septum, which obstructs left ventricular outflow and may also be associated with mitral insufficiency from distortion of the mitral valve leaflets. The condition is inherited and is the most common cause of sudden cardiac death in the Adolescent age-group. The first presentation of hypertrophic cardiomyopathy may be sudden cardiac death, usually during exertion as a result of inadequate cardiac output with increased demand, or patients may present with exertional syncope, shortness of breath, palpitations, chest pain, or dizziness. Cardiac auscultation usually reveals a systolic, crescendo—decrescendo murmur loudest between the left lower sternal border and apex. The degree of left ventricular outflow obstruction is directly related to volume status, so symptoms and prominence of the patient's murmur are decreased with increased preload (e.g., Valsalva maneuver). Obstruction is worsened with decreased preload; therefore, patients will be more symptomatic with dehydration.

Question: 129

A 4-year-old child is admitted to the critical care unit for observation after a closed head injury sustained with a fall from a second-story balcony. Non-contrast head computed tomography reveals a non-depressed parietal skull fracture without intracranial bleeding or cerebral edema

a. Chest and cervical spine x-rays are normal. On arrival to the critical care unit, the patient is somnolent but arousable and well perfused; all vital signs are within normal limits.

Two hours later, the child is tachycardic, has vomited twice, and has developed abdominal distention and abdominal tenderness. The most likely cause of this patient's symptoms is

- A. concussion.
- B. rib fracture.
- C. intra-abdominal injury.
- D. dehydration.

Answer: C

Explanation:

Blunt trauma (e.g., motor vehicle accidents, falls) is far more common in the pediatric population than penetrating trauma (e.g., stab or gunshot injury). Pediatric patients are more susceptible to internal injury (even in the absence of external signs of trauma) because of a decreased amount of protective subcutaneous fat and muscle tissue, the relatively anterior position of intra-abdominal organs, and greater flexibility of the pediatric musculoskeletal system, which allows for deeper penetration of traumatic force. Children are also more likely to sustain head injury during a fall because they have a larger head size relative to the rest of the body. Diagnosis of intra-abdominal injury in the pediatric patient is often delayed because of a developmental inability to report focal discomfort and the ability of the pediatric cardiovascular system to compensate for hemorrhage. Reassessment is crucial in the pediatric trauma patient to detect injuries that may have been missed during the initial assessment and resuscitation. Intra-abdominal injury (e.g., bowel contusion/perforation, hepatic and splenic injuries) may lead to distention, tenderness, respiratory distress, and signs of hemorrhagic shock (e.g., falling hematocrit, tachycardia, hypotension).

Question: 130

Which of the following statements regarding the use of inotropic agents in the critically ill pediatric patient is most accurate?

- A. Inotropic agents should be initiated before fluid resuscitation in patients with hypovolemic shock
- B. Dobutamine infusion is contraindicated in patients with cardiogenic shock
- C. Milrinone administration requires less invasive monitoring than other inotropic agents
- D. Inotropic agents, such as dopamine and norepinephrine, with vasoconstrictive effects may be indicated in patients with septic shock

Answer: D

Explanation:

Inotropic medications are used primarily in the setting of shock. Inotropes increase the contraction force of the myocardium and may cause peripheral vasodilation or constriction, depending on the medication. Dopamine is used in almost every type of shock and has variable dose-dependent effects. At low doses, dopamine primarily leads to end-organ vasodilation. At midrange doses, dopamine acts on beta-1 receptors and exerts inotropic and chronotropic effects, leading to increased cardiac output. At high doses, dopamine primarily affects alpha receptors, leading to increased blood pressure from peripheral vasoconstriction. Norepinephrine is a strong alpha-agonist, causing peripheral vasoconstriction, and acts on cardiac beta-1 receptors as well, increasing cardiac contractility and heart rate. Dobutamine is primarily an inotrope, acting on beta-1 receptors to increase cardiac contractility, and is used primarily in the setting of cardiogenic shock.

Milrinone is a phosphodiesterase inhibitor and works by increasing intracellular cyclic adenosine monophosphate, leading to increased cardiac contractility and peripheral vasodilation. The phosphodiesterase inhibitors are associated with a significantly increased risk of cardiac arrhythmias, and therefore, patients receiving milrinone would require continuous careful monitoring during administration.

Question: 131

A nurse is taking care of a 7 -year-old patient with heart failure who is being treated with diuretics. Because of the diuretic therapy, the critical care nurse knows that this child needs close monitoring for

- A. cardiac enzymes.
- B. overall fluid status.
- C. serum white blood cell count.
- D. pulmonary compliance.

Answer: B

Explanation:

Diuretics increase urine output by increasing renal sodium (and water) excretion. They may be used in a variety of clinical conditions, including congestive heart failure, bronchopulmonary dysplasia, hypertension, and primary renal disease. There are three classes of diuretic medications, which are differentiated by their mechanism and site of action in the kidney. Thiazide diuretics (e.g., chlorothiazide) block reabsorption of sodium in the distal tubule, leading to potassium wasting and hypokalemia in addition to the diuretic effect. Loop diuretics (e.g., furosemide) inhibit sodium reabsorption in the proximal renal tubule and may also cause hypokalemia, although to a lesser degree than with thiazide diuretics. Finally, potassium-sparing diuretics (e.g., spironolactone) work via antagonism of aldosterone effects in the distal tubule. The overall fluid balance and the effect of fluid shifts from diuretic administration require close monitoring in the critically ill pediatric patient to avoid the complications of electrolyte abnormalities and reduced intravascular volume.

Question: 132

The hospital administration has decided to replace all of the defibrillators with a new model because of concerns about quality. Which of the following methods is most effective for preparing the nursing staff for the defibrillator change?

- A. Formal teaching sessions about the new defibrillators
- B. Prominent display of both written and visual instructions on each new machine
- C. Hands-on teaching/demonstration sessions
- D. Lecture-style teaching sessions by a representative of the defibrillator company

Answer: C

Explanation:

Educational opportunities provided to nursing staff should be designed to maximize effective transmission of critical information to staff and to provide hands-on practice so that important clinical skills can be honed in the educational setting, allowing for effective and confident practice in the patient care setting.

When new equipment is introduced, plenty of time must be allowed for staff to learn about equipment use. to ask questions as difficulties arise, and to use the equipment in an educational setting. Whenever possible. this should be accomplished before the changes take place to avoid a rough transition as new skills and practices are implemented.

Question: 133

The mother Of a 3-day Old infant girl would like to breastfeed after the child's surgical repair Of a myelomeningocele and ventriculoperitoneal shunt placement. The child is awake and alert and has been cleared to resume feeding. The most appropriate response by the nurse to this request is to tell the mother

- A. that myelomeningocele repair is a contraindication for breastfeeding.
- B. how to position the infant for breastfeeding so that the infant is not lying on her back
- C. that the infant can only take pumped breast milk through a bottle.
- D. that the infant requires more calories than breast milk can provide.

Answer: B

Explanation:

Infants who have undergone myelomeningocele repair generally require side-lying or prone positioning until the surgical wound has healed sufficiently. Resuming normal feedings. including breastfeeding, should be started as soon as possible after surgical repair. All of the benefits of breastfeeding in the normal infant also apply to the infant with myelomeningocele and an early return to breastfeeding should be encouraged. Mothers can be taught how to position themselves and their infant so that the infant is not lying supine on the surgical wound. Although some newborns require fortified feedings for growth concerns, this is not typically a major concern in the infant with myelomeningocele.

Question: 134

A 4-year-old girl with type I diabetes mellitus is treated with intravenous fluids and continuous insulin administration for diabetic ketoacidosis. Four hours after admission, she is alert, and her serum electrolytes and glucose are normalizing. Eight hours after admission, she begins to complain of headache and seems tired. Two hours later, she develops bradycardia and extremity posturing. On the basis of this information, the critical care nurse suspects that the patient has developed

- A. seizure activity from the hypoglycemia.
- B. hyperkalemia.
- C. cerebral edema.
- D. hyperosmolar coma.

Answer: C

Explanation:

Cerebral edema is a rare but potentially fatal complication of diabetic ketoacidosis (DKA), occurring in up

to 1% of pediatric patients with DKA. Risk factors for the development of cerebral edema in the setting of DKA are not entirely clear despite the attempts of numerous studies to identify clear etiologic factors. Young age, rapid correction of hyperglycemia and dehydration, and a severe degree of acidosis on initial presentation have all been thought to play a role in the development of cerebral edema. Classically, symptoms of cerebral edema (e.g., lethargy, headache, altered mental status, bradycardia) develop several hours after the initiation of therapy and can rapidly progress to brain herniation and death. Prompt treatment for increased intracranial pressure as soon as the patient exhibits signs of cerebral edema offers the best chance of recovery, including intravenous mannitol, head-of-bed elevation, hyperventilation, and invasive intracranial monitoring if indicated.

Question: 135

A 15-month-old immunized child is admitted with viral croup. She is treated with a single dose of nebulized racemic epinephrine and dexamethasone in the emergency department. Initial assessment upon transfer to the critical care unit 2 hours later reveals an alert toddler with moderate inspiratory stridor at rest and moderate suprasternal and intercostal retractions. Respiratory rate is 32 breaths/min; heart rate is 140 beats/min; and pulse oximetry reveals an oxygen saturation of 98% on room air. Appropriate management of this patient consists of

- A. nebulized albuterol.
- B. cool mist and observation.
- C. intubation.
- D. additional nebulized racemic epinephrine.

Answer: D

Explanation:

Croup is characterized by laryngeal inflammation and edema in association with a viral upper respiratory infection. Clinically, patients usually present with symptoms of upper respiratory infection, a hoarse voice, and a "barky" or "brassy" cough. Depending on the degree of upper airway inflammation, inspiratory stridor and retractions may also be present. Symptoms are classically worse at night and with patient agitation. Patients with mild symptoms without respiratory distress are treated with corticosteroids (e.g., dexamethasone) administered orally or intramuscularly. More serious cases (e.g., respiratory distress, stridor at rest) are treated with nebulized racemic epinephrine, corticosteroids, and potentially inhaled heliox. Intubation and mechanical ventilation for respiratory failure are rarely required with viral croup. The patient described in the question is in moderate respiratory distress and, thus, should continue with the corticosteroids and the nebulized racemic epinephrine. Respiratory failure does not appear imminent given that the patient is maintaining oxygenation, adequate respiratory effort, and normal mental status. Intubation is, therefore, not indicated at this point, although the patient's respiratory status requires close monitoring for any deterioration. Beta-agonist bronchodilators, such as albuterol, do not generally improve the upper airway edema associated with croup.

Question: 136

The father of a 13-year-old patient who is brain dead after a submersion injury tells the medical staff that he is certain his child will recover fully despite what they have told him about the prognosis. The nurse's best action in this case is to

- A. recommend to family members to consider A psychological evaluation for the father.
- B. encourage the patient's father to hope for A miracle.
- C. maintain an ongoing relationship with the father to assist him in coming to terms with the expected outcome.
- D. ask the medical team to confirm brain death with tests to convince the father.

Answer: C

Explanation:

Families are often overwhelmed in the setting of unexpected severe disease or grave prognostic predictions with regard to their child. Initial denial and anger are normal, and common reactions to such traumatic family events and should be treated as such in the critical care unit. One of the most important roles of the critical care nurse is assisting the family to come to terms with the expected or actual clinical outcome. This process cannot be hurried but can be made much more tolerable with the assistance of the nurse who creates an accepting and supportive environment in the setting of a tragic diagnosis.

Question: 137

Inhaled nitric oxide administration in the critical care unit is most appropriate in which of the following clinical situations?

- A. Methemoglobinemia
- B. Idiopathic pulmonary hemorrhage
- C. Pulmonary hypertension
- D. Cerebrovascular accident

Answer: C

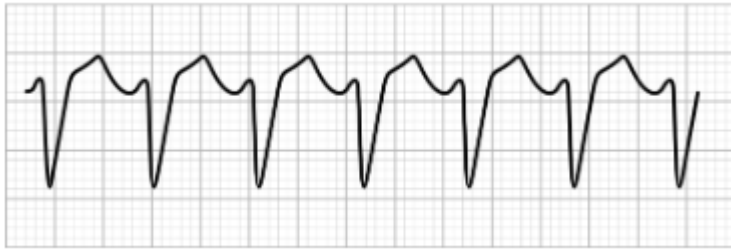Explanation:

Inhaled nitric oxide (NO) is a potent pulmonary vasodilator (via smooth muscle relaxation) that is used primarily in the setting of severe arterial hypoxemia or pulmonary hypertension. Inhaled NO increases arterial oxygenation by improving pulmonary blood flow to well-ventilated alveoli, thereby improving ventilation/perfusion matching. Inhaled NO diffuses into the pulmonary vasculature, where it combines with oxyhemoglobin to form methemoglobin and nitrate, which enter the systemic circulation. Methemoglobinemia may lead to impaired tissue oxygen delivery and worsening hypoxia. Nitric oxide also inhibits platelet aggregation and may worsen a bleeding diathesis. Contraindications to inhaled NO therapy include intractable hypotension and serious bleeding disorders, including pulmonary hemorrhage or disseminated intravascular coagulation.

Question: 138

A 10-year-old patient who has been admitted to the critical care unit with viral myocarditis acutely develops diaphoresis, pallor, and decreased responsiveness. Vital signs reveal a heart

rate of 190 beats/min, a respiratory rate of 50 breaths/min, and blood pressure of 82 /30 mmHg. Carotid and femoral pulses are palpable. The cardiac monitor reveals the following rhythm:



Which of the following interventions is most appropriate?

- A. Intravenous beta-blocker administration
- B. Immediate cardioversion
- C. Intravenous epinephrine administration
- D. Vagal maneuvers

Answer: B

Explanation:

The rhythm strip that accompanies the question demonstrates a regular, wide-complex tachycardia consistent with monomorphic ventricular tachycardia. Additional electrocardiogram findings that may suggest ventricular tachycardia include atrioventricular dissociation, fusion beats (i.e., a mixed-appearance QRS complex resulting from simultaneous conduction of A normal and aberrant impulse), and capture beats (i.e., a normal QRS complex in the midst of the arrhythmia from lucky timing of the atrial impulse relative to the aberrant pathway). Stable ventricular tachycardia is characterized by hemodynamic stability with no evidence of end-organ compromise and is treated initially with antiarrhythmic medications. Synchronized cardioversion may be used if the arrhythmia continues or if the patient deteriorates. Unstable ventricular tachycardia is characterized by hemodynamic instability or evidence of decreased perfusion to critical end-organs. The patient described in the question is demonstrating altered responsiveness consistent with inadequate brain perfusion and is hypotensive. This patient requires emergent synchronized cardioversion. Pulseless ventricular tachycardia is treated with emergent defibrillation. Beta-blocker medications may be administered to the patient with stable ventricular tachycardia but are not indicated initially in the unstable patient. Epinephrine is indicated in the management of pulseless ventricular tachycardia only after initial emergent defibrillation.

Question: 139

A 10-year-old previously healthy child has a generalized tonic—clonic seizure that ended spontaneously after 6 minutes. Immediately afterward, the child is combative and confused. Appropriate management of this patient consists of

- A. placing the child in physical restraints.
- B. providing calm reassurance while continuing to monitor the patient.
- C. administering rectal diazepam.
- D. administering intramuscular haloperidol.

Answer: B

Explanation:

The period immediately following a seizure, the postictal period, is often characterized by lethargy, disorientation, and combativeness. Supportive management and ongoing reassurance assist the postictal patient through this transient phase. Helping the patient get reoriented to his or her surroundings in a calm manner may also help with the disorientation that occurs. Physical restraints are rarely indicated unless the patient is likely to do harm to him- or herself or the staff, despite attempts to calm the patient. Additionally, the metabolic stress that a prolonged seizure causes will be exacerbated if a postictal patient is fighting restraints. Rectal diazepam is generally not indicated for postictal behavioral changes but may be used to manage an ongoing seizure, Haloperidol is not indicated for the agitation and combativeness associated with the postictal period.

Question: 140

When caring for a bone marrow transplant patient who develops fever and hypotension, the critical care nurse administers which of the following regimens?

- A. A narrow-spectrum, antibacterial agent to avoid antibiotic-resistant organisms
- B. Supportive care without antibiotics unless a culture grows a specific organism
- C. Broad-spectrum, multiagent, antibacterial therapy
- D. An intravenous antifungal agent

Answer: C

Explanation:

Empiric antibiotics in the seriously ill or immunocompromised patient should cover a broad range of potential infectious agents until a specific organism is isolated. Antibiotic treatment can be narrowed once the etiology is identified or the patient is improving. Bone marrow transplant patients are at risk for bacterial, viral, and fungal opportunistic infections. This immunocompromised patient is febrile and hypotensive, consistent with sepsis, and requires aggressive treatment to avert further deterioration. Although concerns about antibiotic resistance are important on a public health level, it is inappropriate to use narrow-spectrum antibiotics or hold off on antibiotic administration in the critically ill septic patient. Although empiric antifungal therapy may be warranted in this patient, it should be combined with antibacterial agents until culture results are known.

Question: 141

A 3-year-old boy is evaluated after an accidental submersion injury. A family member reports leaving the bathroom while he was in the bathtub and returning "just a little while later" to find him submerged. When they pulled him out, he was blue and unresponsive. A family member performed cardiopulmonary resuscitation for 1—2 minutes, at which point the child began breathing spontaneously. Upon arrival to the hospital 45 minutes after the initial event, the child is appropriate but appears tired with a heart rate of 140 beats/min, respiratory rate of 36 breaths/min, oxygen saturation of 95% on room air, and blood pressure of 90/ 50 mmHg. Appropriate management of this patient consists of

- A. supplemental oxygen administration, chest x-ray, intravenous line placement, and close inpatient monitoring.
- B. observation in the emergency department for 1–2 hours with discharge home unless the patient's status worsens.
- C. endotracheal intubation with invasive intracranial pressure monitoring in the critical care unit.
- D. early administration of intravenous antibiotics.

Answer: A

Explanation:

The child described in the question is being evaluated shortly after a significant submersion injury, which required cardiopulmonary resuscitation at the scene of the event. Patients who did not require significant resuscitation after a submersion injury and are asymptomatic 6 hours after the event are appropriate for discharge. Any patient who is symptomatic (e.g., hypoxia, tachypnea, respiratory distress, altered mental status) should be treated and monitored in the inpatient setting. This patient is maintaining his airway but demonstrates tachypnea and mild hypoxia. Mental status is adequate but requires close monitoring. Appropriate management of this patient consists of intravenous placement for support of hydration, supplemental oxygen administration, and monitoring for signs of respiratory deterioration. Prophylactic antibiotics are not generally indicated in the initial management of a submersion injury. Patients may require intravascular volume replacement, mechanical ventilation, and intracranial hypertension management. The long-term prognosis with a submersion injury is primarily determined by the degree of cerebral hypoxic injury. Patients who continue to need cardiopulmonary resuscitation on arrival to the hospital have markedly decreased rates of neurologic recovery and survival.

Question: 142

A 14-year-old patient hospitalized after an intentional drug overdose confides to you that she has been sexually abused by a family member and has never disclosed this information before. She asks you not to tell anyone because she feels certain that her family would not believe her. In this situation, the nurse should

- A. maintain patient confidentiality as legally required since the patient can seek medical care without parental consent for conditions relating to sexual activity.
- B. inform the patient that the nurse is legally obligated to report the abuse, while providing reassurance that the patient will be supported through the disclosure process.
- C. tell the patient that her disclosure will be kept confidential. and then tell the patient's family at the earliest opportunity.
- D. ask the medical team to screen the patient for sexually transmitted diseases and pregnancy without disclosing the abuse.

Answer: B

Explanation:

One of the obligations of any professional who works with children, including medical care providers, is the mandatory reporting of suspected or reported child abuse or sexual abuse. Although the law in most states recognizes the legal rights of Adolescent patients to seek confidential medical care when it involves sexual

activity, pregnancy, and drug or alcohol treatment, those rights do not negate the reporting requirements with regard to abuse or rape of the pediatric patient. Although the health care provider is required to report the abuse to the appropriate child protective services agency, he or she is not required to disclose the abuse to the patient's family. In most circumstances, a trusted adult member of the family can be identified by the patient, and medical or social work staff can assist the patient in disclosing the abuse and seeking support with the help of the trusted adult family member.

Question: 143

A 16-year-old healthy girl is 31 weeks pregnant when she suddenly develops right-sided chest pain worse with inspiration and dry cough. Respiratory examination reveals a respiratory rate of 32 breaths/min with clear breath sounds bilaterally. Heart rate is 130 beats/min with no appreciable murmurs, rubs, or gallops on cardiovascular examination. Chest x-ray is normal. The electrocardiogram demonstrates sinus tachycardia but is otherwise normal. The most likely explanation for her symptoms is

- A. pulmonary embolism.
- B. anxiety.
- C. normal pregnancy.
- D. pneumonia.

Answer: A

Explanation:

Acute pulmonary embolus is seen uncommonly in the general pediatric population. Medical conditions that increase the risk of pediatric acute pulmonary embolism include pregnancy (as in the case described in the question), sickle cell disease, malignancy, underlying hypercoagulable disorder, oral contraceptive use (particularly in a patient who smokes cigarettes), vasculitis, and nephrotic syndrome. This patient's clinical presentation is consistent with pulmonary embolus: acute onset of pleuritic, unilateral, chest pain; cough; tachypnea; and sinus tachycardia. Chest x-ray can be normal or may demonstrate a focal infiltrate, pleural effusion, or atelectasis. In the patient with a high probability of pulmonary embolus, ventilation perfusion scan, helical computed tomography scan, or angiography may be used to confirm the diagnosis. Although anxiety may present with chest pain, shortness of breath, and tachycardia, it should be a diagnosis of exclusion. Normal pregnancy is often associated with tachypnea and shortness of breath from restricted pulmonary excursion as the uterus grows but is not generally associated with the acute onset of chest pain. Pneumonia would not typically present suddenly.

Question: 144

A 12-month-old child with severe dehydration and hypovolemic shock has an intraosseous (10) needle placed in the proximal tibia during initial resuscitation efforts. Management of the 10 needle in this patient includes

- A. wrapping the entire lower extremity in gauze to minimize the risk of infection.
- B. removing the 10 needle after 3 hours, regardless of whether or not other vascular access has been established.
- C. decreasing the rate of fluid infusion through the 10 needle if the calf area develops swelling.

D. removing the 10 needle as soon as alternate vascular access has been established.

Answer: D

Explanation:

Intraosseous (10) cannulation is extremely useful in the unstable pediatric patient in whom intravenous vascular access is not readily obtainable. Intravenous fluids, vasoactive medications, and blood products may all be administered through an 10 needle. The 10 needle is placed into the bone marrow of one of the patient's long bones, typically the proximal tibia. The most common complication of 10 needle placement is extravasation of fluid into the soft tissues when the needle is inserted through the bone or becomes dislodged after initial proper placement. Unrecognized extravasation may lead to compartment syndrome or tissue necrosis if medications associated with tissue damage extravasate. Less commonly, 10 needle placement may be associated with cellulitis, osteomyelitis, or injury to the bony growth plate. The 10 needle insertion site and adjacent soft tissues should be examined frequently while the 10 needle is being used. The 10 needle should be removed if there is concern for extravasation of fluid or medication. Once alternate vascular access has been established, the 10 needle should be removed.

Question: 145

A 2-day old infant born to a woman who had no prenatal care develops progressive respiratory distress, lethargy, poor perfusion, and cyanosis. An echocardiogram reveals hypoplastic left heart syndrome. Which of the following interventions is most appropriate?

- A. Obtain samples for blood typing in anticipation of cardiac transplantation
- B. Endotracheal surfactant administration
- C. Intravenous broad-spectrum antibiotic administration
- D. Intravenous prostaglandin E: administration

Answer: B

Explanation:

Hypoplastic left heart syndrome is characterized by severe underdevelopment of the left ventricle and ascending aorta. Aortic coarctation is frequently present in patients with hypoplastic left heart syndrome. Systemic circulation is dependent on a widely patent ductus arteriosus (PDA) and interatrial shunting (e.g., atrial septal defect). After delivery, oxygenated blood returning to the left atrium is unable to flow normally into the left ventricle and flows instead through an interatrial shunt to the right atrium, where it mixes with systemic venous blood and is pumped to the pulmonary artery. It then flows into the pulmonary circulation or into the systemic circulation by the PDA, depending on the pressure gradient between the systemic and pulmonary circulations. Infants typically present in the first 2 days of life with severe cardiogenic shock (if the diagnosis is not known prenatally) as the PDA begins to close. Initial treatment involves prostaglandin administration to maintain systemic circulation by the PDA. Definitive treatment consists of a three-stage surgical repair (Norwood/bi-directional Glenn/Fontan) or cardiac transplantation.

Question: 146

In which of the following clinical scenarios is it most appropriate to use four-point mechanical restraints?

- A. An 8-year-old patient screams and hits his mother as she tries to help him take an oral medication he does not like
- B. A 15-year-old patient with alcohol intoxication continues to punch and kick staff despite multiple attempts to calm him
- C. A 17-year-old patient who is combative after a prolonged seizure yells loudly and disturbs other patients
- D. A 12-year-old patient with anorexia nervosa refuses the placement of a nasogastric tube for involuntary feedings

Answer: B

Explanation:

Occasionally, mechanical or pharmacologic restraints are required for the pediatric patient to limit aggressive behavior that is placing the patient or others in imminent danger. This may occur in association with behavioral or psychiatric conditions or an acute medical illness, such as head injury, intoxication, or trauma. The American Academy of Pediatrics emphasizes that restraints are used if there is a clear indication, a safe application, and a consideration of alternatives as well as clear reassessment guidelines. Four-point mechanical restraints are not appropriate in the child who is resisting oral medication or in the patient who is a verbal disturbance. Patients requiring nasogastric tube placement for a medical emergency (e.g., toxic ingestion in which timely administration of activated charcoal is required) may require mechanical restraints to allow for medical care, but it would not be the first choice in the anorexic adolescent. The intoxicated patient who is a physical threat to himself and staff despite nonmechanical attempts to calm him is an appropriate candidate for short-term use of four-point restraints.

Question: 147

The critical care nurse notices a gradual increase in the number of hospital-acquired infections in patients in the critical care unit. Which of the following interventions is most helpful in this situation?

- A. Anonymously inform the hospital accreditation organization
- B. Review the relevant clinical research so that the nurse can help formulate a more standardized, effective clinical policy for hand-cleaning and sterile procedures
- C. Ensure that the nurse is personally washing his or her hands and using sterile technique more effectively
- D. Start keeping track of which medical providers are taking care of the patients with hospital-acquired infections so that they can be approached directly about their practices

Answer: B

Explanation:

Identifying potential barriers to the best patient care, evaluating evidence-based research and outcome data, and embracing a leadership role in implementing policies and procedures that result in improved patient safety are important components of best nursing practice. Although it is important for all providers to optimize their individual compliance with established safety practices, it is far more effective for challenges to be identified and addressed on a larger scale. Punitive models of identifying problems in patient care impair staff members' willingness to identify mistakes and problems when they occur and make it more difficult for the nursing staff to learn from the inevitable mistakes that occur in the critical care setting.

Question: 148

A critical care nurse monitors a 12-year-old patient who is recovering from an upper endoscopy for evaluation of hematemesis. Several hours after the procedure, the patient develops progressively worsening upper abdominal pain, tachycardia, and abdominal distention. Which of the following actions by the nurse would be most appropriate in this situation?

- A. Immediately notify the patient's physician of a likely post-procedure complication
- B. Request an order for intravenous pain medication to treat the patient's normal post-procedure pain
- C. Coach the patient through nonpharmacologic pain management strategies, such as visualization and deep breathing
- D. Assist the patient in ambulating around the room to help with passing gas through the gastrointestinal tract

Answer: A

Explanation:

Although serious complications after esophagogastroduodenoscopy (EGD) are uncommon, knowledge of the expected or typical clinical course after a surgical procedure can help with early recognition when a complication arises. Mild sore throat and transient abdominal bloating are common after upper endoscopy. Concerning symptoms requiring further evaluation include fever, subcutaneous air/crepitus of the neck or chest, vomiting, Abdominal distention and rigidity, severe sore throat or difficulty swallowing, and severe abdominal pain. Worsening abdominal pain with distention in this case is concerning for intestinal perforation and requires urgent evaluation. Uncommon but serious complications after EGD also include bleeding, aspiration, and infection, Complications of procedural sedation, such as respiratory depression. agitation. and cardiac arrhythmias, may also be seen.

Question: 149

A teenage boy is in the critical care unit with chest and abdominal trauma after being struck by a car. He has a chest tube placed for drainage of a large left hemothorax. This patient's care should also include which of the following interventions?

- A. Make sure the drainage collection chamber is above the patient's chest level
- B. Ensure that the patient moves as little as possible
- C. Monitor the volume and quality of chest tube drainage material
- D. Frequently clamp the existing chest tube

Answer: C

Explanation:

Chest tubes are placed in patients requiring drainage of pleural air (i.e., pneumothorax) or fluid (i.e., pleural effusion, hemothorax, empyema). A common chest drainage unit consists of the suction control, fluid collection, and water seal chambers. The drainage collection chamber should be maintained below the patient's chest level to allow gravity to assist with fluid drainage. An important part of caring for the patient with a chest tube is close monitoring of both the volume and quality of chest tube drainage. If the patient is

able to do so, changing positions can enhance drainage of the pleural fluid or blood. Frequent chest tube clamping while the patient needs drainage should be avoided, as it prevents chest tube drainage and can contribute to the development of a tension pneumothorax. Occasional brief chest tube clamping may be performed to isolate the source of an air leak, and the chest tube may be clamped before anticipated removal.

Question: 150

A 13-month-old patient with pneumococcal sepsis continues to deteriorate despite maximal intensive care. She has developed acute respiratory distress syndrome; urine output is poor; and serum creatinine is rising steadily. Liver function tests are elevated, and she is coagulopathic. This patient's clinical status is best characterized as

- A. toxic shock syndrome.
- B. compensated shock.
- C. multiple organ dysfunction syndrome.
- D. urosepsis.









Answer: C

Explanation:

Multiple organ dysfunction syndrome (MODS) represents the more severe end of the sepsis syndrome spectrum and is characterized by progressive physiologic derangements in at least two organ systems, in this case secondary to sepsis. Multiple organ dysfunction syndrome may be primary, in response to the original insult (e.g., sepsis) or secondary, occurring as a result of the body's inflammatory response to the initial insult. Acute respiratory distress syndrome is almost always present with MODS, but any organ system may be affected. Cardiovascular involvement may lead to poor cardiac function and refractory hypotension; renal involvement leads to oliguric renal failure, which may require dialysis; hematologic involvement leads to disseminated intravascular coagulation; and hepatic involvement is characterized by elevated liver function tests and coagulopathy.

For More Information – **Visit link below:**
<https://www.certsgrade.com/>

PRODUCT FEATURES

-  **100% Money Back Guarantee**
-  **90 Days Free updates**
-  **Special Discounts on Bulk Orders**
-  **Guaranteed Success**
-  **50,000 Satisfied Customers**
-  **100% Secure Shopping**
-  **Privacy Policy**
-  **Refund Policy**

16 USD Discount Coupon Code: **NB4XKTMZ**

