

AAVSB

VTNE

Veterinary Technician National Exam

Questions And Answers PDF Format:

For More Information – Visit link below:

<https://www.certsgrade.com/>

Version = Product



Latest Version: 6.0

Question: 1

Which of the following terms is used to describe a condition that is long-lasting and usually develops over time?

- A. Terminal
- B. Transient
- C. Chronic
- D. Acute

Answer: C

Explanation:

Chronic conditions are long-lasting and usually develop over time.

Acute conditions have a rapid onset and/or last for only a short period of time.

Terminal conditions cannot be cured and will result in death.

Transient conditions last for a short period of time and do not necessarily need treatment.

Reference:

Joanna M. Bassert, VMD. McCurnin's Clinical Textbook for Veterinary Technicians, 9th Edition. Pg 638.

Question: 2

What is the term used to describe a patient's condition involving painful and paradoxical breathing?

- A. Dysphoria
- B. Hyperventilation
- C. Flail chest
- D. Hypoventilation

Answer: C

Explanation:

Flail chest is when a section of the ribs becomes unattached to the chest wall, and involves painful and paradoxical breathing. Paradoxical breathing is a result of the flail segment moving in the opposite direction of the rest of the chest wall due to pressure variances inside the chest. Taking a normal breath becomes very painful for patients experiencing paradoxical breathing.

Hyperventilation is associated with rapid or deep breathing.

Hypoventilation is associated with slow or shallow breathing.

Dysphoria is abnormal mentation, typically associated with anesthetic recovery.

Reference:

Joanna M. Bassert, VMD. McCurnin's Clinical Textbook for Veterinary Technicians, 9th Edition. Pg 842.

Question: 3

Apomorphine is a medication commonly used in canine patients for which of the following?

- A. Pain
- B. Emesis
- C. Constipation
- D. Seizures

Answer: B

Explanation:

Apomorphine hydrochloride is an emetic medication commonly used in canine patients.

Apomorphine hydrochloride is not indicated for seizures, constipation, or pain.

Reference:

Joanna M. Bassert, VMD. McCurnin's Clinical Textbook for Veterinary Technicians, 9th Edition. Pg 900.

Mosby's Comprehensive Review for Veterinary Technicians 5th Edition. Pg 438-439.

Question: 4

If a veterinarian was performing a routine dissection of fibrous tissue (for example, the linea alba), which type of scissors would most likely be used?

- A. Lister scissors
- B. Metzenbaum scissors
- C. Iris scissors
- D. Mayo scissors

Answer: D

Explanation:

Mayo scissors are most often used for routine dissections. Mayo scissors are heavy-duty scissors, used to cut fascia tissue and other dense tissues.

Metzenbaum scissors are used for delicate dissections, such as cutting through thin muscle and fat tissue.

Iris scissors are used for fine detailed ophthalmic work.

Lister scissors are used for cutting bandages.



Reference:

Joanna M. Bassert, VMD. McCurnin's Clinical Textbook for Veterinary Technicians, 9th Edition. Pg 1067.
Mosby's Comprehensive Review for Veterinary Technicians 5th Edition. Pg 528.

Question: 5

Which of the following is the most comprehensive choice for the routine assessment of thoracic trauma following HBC (hit by car) of a dog?

- A. Contrast radiography
- B. Ultrasonography
- C. Survey radiography
- D. Computed tomography

Answer: C

Explanation:

Survey radiographs are quick, non-invasive, and usually do not require sedation/anesthesia. They can assess musculoskeletal structures, pleural space, cardiorespiratory tissues, and diaphragmatic integrity. Ultrasonography is also quick, non-invasive, and usually does not require sedation/anesthesia. In skilled hands, the pleural space, pulmonary surfaces, cardiovascular structures, and diaphragm can be evaluated. Ultrasound cannot evaluate bones for traumatic injury and does not completely assess the lungs.

Contrast radiography is not indicated for routine use, only in rare circumstances where specific pathology indicates. Injectable water-soluble organic iodide contrast agents should only be administered to patients that are hydrated and have stable cardiovascular status.

Computed tomography provides all the benefits of survey radiographs and more, but requires deep sedation to general anesthesia and cost precludes its routine use.

Reference:

Joanna M. Bassert, VMD. McCurnin's Clinical Textbook for Veterinary Technicians, 9th Edition. Pg 516.

Question: 6

What procedure is commonly used for severe cases of ocular squamous cell carcinoma (OSCC) in cattle?

- A. Chemotherapy
- B. Immunotherapy
- C. Extirpation
- D. Cryotherapy

Answer: C

Explanation:

Extirpation, which has largely replaced the term enucleation, is the process of removing all contents within the eye socket. Because cosmetics is usually not a consideration, it is common for extirpation to be the treatment of choice for cattle with OSCC.

Cryotherapy, immunotherapy, and chemotherapy are all types of treatment used in less advanced forms of OSSC.

Reference:

Joanna M. Bassert, VMD. McCurnin's Clinical Textbook for Veterinary Technicians, 9th Edition. Pg 1210.

Mosby's Comprehensive Review for Veterinary Technicians 5th Edition. Pg 640.

The majority of scalpel blades have curved cutting surfaces. Which blade has a triangular shape and pointed tip that is best suited for stabbing incisions and tiny cuts?

Question: 7

- A. #11
- B. #12
- C. #15
- D. #10

Answer: A

Explanation:

A #10 blade has a long, convex cutting edge and is used for large soft tissue incisions. A #15 blade has a similar shape, but is smaller than a #10, so is better with smaller incisions. A #12 blade is sickle shaped with the cutting surface on the concave interior aspect. It is used when incising along periosteal surfaces (for example, onchyectomy and gingival flap elevation). Some prefer using #12 blades for suture removal over scissors.

Reference:

Joanna M. Bassert, VMD. McCurnin's Clinical Textbook for Veterinary Technicians, 9th Edition. Pg 1062.

Question: 8

Which of the following often results in an emergency cesarean section?

- A. Dysbiosis
- B. Distocclusion
- C. Dystocia
- D. Dyspnea

Answer: C

Explanation:

Dystocia, the medical term used to describe a difficult or abnormal birth, often results in an emergency cesarean section. Patients may first be monitored by the emergency clinician for signs of progress with medical management, but if the patient is still unable to deliver, cesarean section is often deemed necessary.

Dyspnea is the medical term used to describe difficult breathing.

Distocclusion is a malocclusion in which the maxilla is longer than the mandible.

Dysbiosis is an imbalance in the bacteria of the gastrointestinal tract.

Reference:

Joanna M. Bassert, VMD. McCurnin's Clinical Textbook for Veterinary Technicians, 9th Edition. Pg 1310.

Mosby's Comprehensive Review for Veterinary Technicians 5th Edition. Pg 668-669.

Question: 9

Which of the following is not a limiting factor in the practicality of measuring intra-arterial blood pressure?

- A. Equipment cost
- B. Technician time
- C. Iatrogenic risks
- D. Technical difficulty

Answer: B

Explanation:

Intra-arterial blood pressure monitoring is highly accurate and a gold standard for monitoring anesthetized patients. It can be technically difficult to perform, but does not take long once proficiency develops. Specialized equipment monitoring is needed; most routine anesthetic monitors do not have this capability. There is a risk of causing iatrogenic injuries (hemorrhage, ischemia, infection, embolization, and vascular insufficiency), so the risks and benefits of the procedure should be weighed carefully.

Reference:

Joanna M. Bassert, VMD. McCurnin's Clinical Textbook for Veterinary Technicians, 9th Edition. Pg 857.

Question: 10

What is a potentially significant side effect of acepromazine?

- A. Hyperventilation
- B. Hypovolemia
- C. Hypoxia
- D. Hypotension

Answer: D

Explanation:

Acepromazine is a tranquilizer that blocks alpha-1 adrenergic receptors, leading to peripheral vasodilation and hypotension. This is normally manageable in otherwise healthy patients.

Acepromazine does not change intravascular volume status to cause hypovolemia, depress respiration to cause hypoxemia, or stimulate respiratory rate to cause hyperventilation.

Reference:

Joanna M. Bassert, VMD. McCurnin's Clinical Textbook for Veterinary Technicians, 9th Edition. Pg 1013.
Mosby's Comprehensive Review for Veterinary Technicians 5th Edition. Pg 463-464.

Question: 11

Which of the following describes the intended action of chemotherapy drugs?

- A. Reverse the effect of another substance
- B. Bind to and activate a receptor to produce a response
- C. Suppress vomiting
- D. Kill cells and/or microorganisms

Answer: D

Explanation:

A chemotherapy drug is used to kill cells and/or microorganisms. The term is most commonly thought of when referring to cancer medications, but also includes antimicrobials. Examples include vincristine (cancer) and cephalixin (antibiotic).

Antagonist drugs reverse the effects other substances. Agonist drugs bind to and activate receptors to produce specific responses. For example, hydromorphone is an agonist at opioid receptors and naloxone is its antagonist.

Antiemetic drugs suppress vomiting and can work on the nervous system (centrally) and/or gastrointestinal tract (peripherally). Examples include maropitant and metoclopramide.

Reference:

Joanna M. Bassert, VMD. McCurnin's Clinical Textbook for Veterinary Technicians, 9th Edition. Pg 732, 958.
Mosby's Comprehensive Review for Veterinary Technicians 5th Edition. Pg 438-439.

Question: 12

Which of the following statements regarding swine anesthesia is not true?

- A. Adult pigs have a higher incidence of malignant hyperthermia
- B. Water should be withheld 12-24 hours prior
- C. There are limited superficial veins for drug access
- D. Tracheal intubation is challenging based on their laryngeal anatomy

Answer: B

Explanation:

Water should not be withheld at all. Food should be withheld for 8 to 12 hours in advance of anesthesia. All other statements are true.

Reference:

Mosby's Comprehensive Review for Veterinary Technicians 5th Edition. Pg 643.

Question: 13

What sort of diet is best suited for a patient in renal failure?

- A. A diet high in fat
- B. A diet low in protein
- C. A grain-free diet
- D. A diet low in carbohydrates

Answer: B

Explanation:

A diet low in protein slows the progression of renal disease by reducing the amount of work the kidneys perform to process protein. Protein restriction decreases proteinuria and protects the kidney.

Veterinary patients with renal disease are not placed on a diets that are grain-free, high in fat, or low in carbohydrates.

Reference:

Joanna M. Bassert, VMD. McCurnin's Clinical Textbook for Veterinary Technicians, 9th Edition. Pg 650.

Mosby's Comprehensive Review for Veterinary Technicians 5th Edition. Pg 281.

Question: 14

Laminitis is a disease that generally only occurs in adult horses, and its exact cause is unknown. What part of the horse's body does laminitis directly affect?

- A. Feet
- B. Organs
- C. Joints
- D. Bones

Answer: A

Explanation:

Laminitis, also known as founder, is a disease that directly affects a horse's feet. Laminitis can occur in only the front feet, or in all four feet, and causes the sensitive laminae of the horse's feet to become inflamed. This disease is serious and often life-threatening.

Laminitis is not a disease that directly affects a horse's joints, bones, or organs.

Reference:

Mosby's Comprehensive Review for Veterinary Technicians 5th Edition. Pg 617.

Clinical Anatomy and Physiology for Veterinary Technicians 3rd Edition. Pg 165, 168.

Question: 15

Which wing trimming technique will completely prevent a bird from flight?

- A. Primary and secondary flight feathers
- B. Primary flight feathers
- C. No technique is fully effective
- D. Primary flight feathers on one wing only

Answer: C

Explanation:

No wing trimming technique will completely prevent a bird from some type of flight. Permitting birds to fly gives them sufficient exercise and allows for healthy psychological development.

Trimming the primary and secondary flight feathers will provide the maximal flight restriction in birds, especially lighter birds.

Trimming just the primary flight feathers will help restrict the flight of large, heavier birds.

Trimming the primary flight feathers on only one wing is not recommended since it may injure the bird from uncontrolled flight.

Reference:

Joanna M. Bassert, VMD. McCurnin's Clinical Textbook for Veterinary Technicians, 9th Edition. Pg 773.

Mosby's Comprehensive Review for Veterinary Technicians 5th Edition. Pg 383.

Question: 16

Where is a chest tube normally placed in a canine patient?

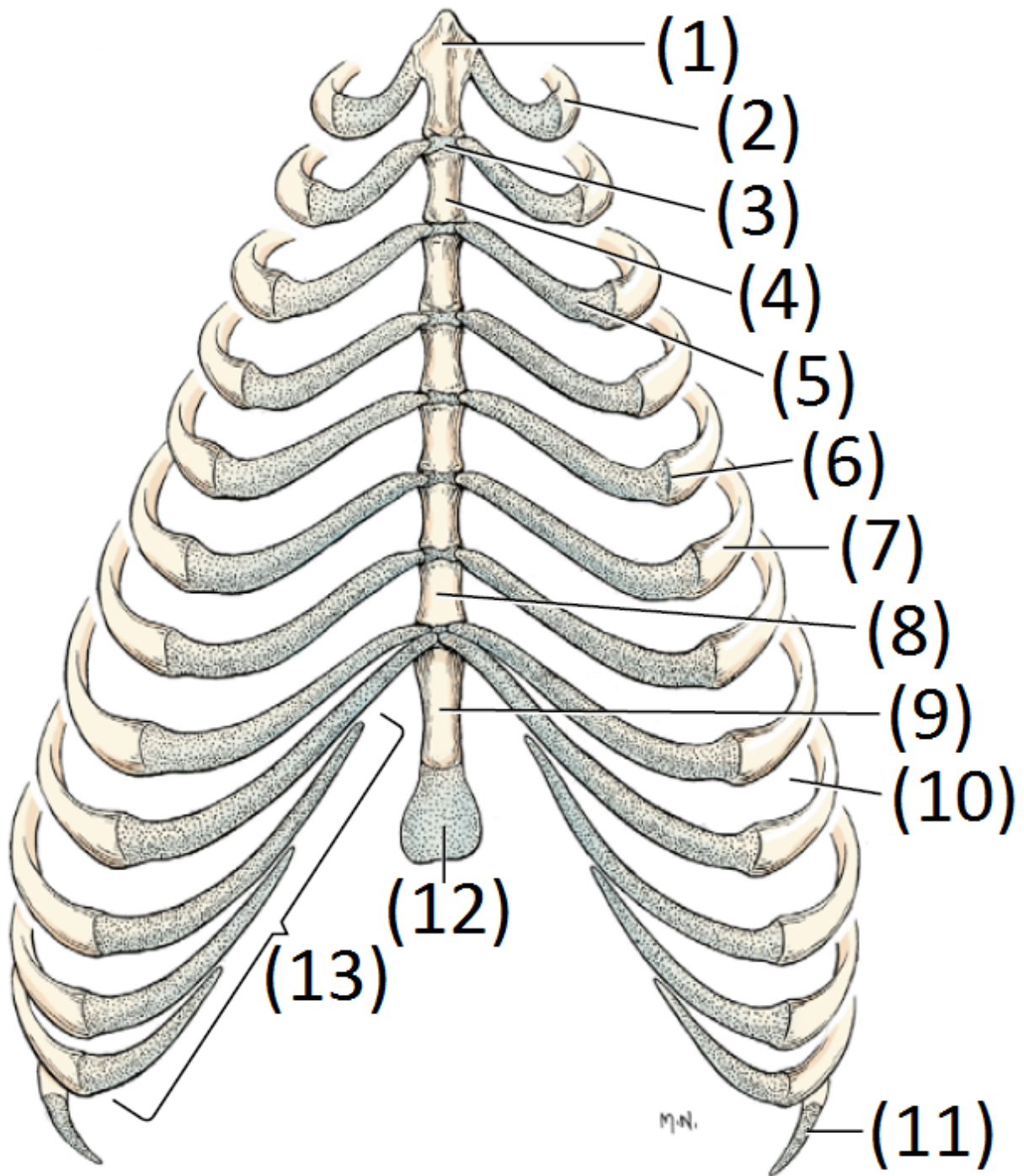
- A. 5th intercostal space
- B. 10th intercostal space
- C. 8th intercostal space
- D. 2nd intercostal space

Answer: C

Explanation:

When a chest tube (thoracic drain) is used for drainage in a canine patient, it is generally placed in the 7th, 8th, or 9th intercostal space.

The chest wall should be clipped of hair and scrubbed with antiseptic solutions. The patient is placed in lateral recumbency. The drain should enter the skin surface at the 10th or 11th intercostal space, then tunnel subcutaneously and penetrate the chest wall at the 7th, 8th, or 9th intercostal space.



Reference:

Joanna M. Bassert, VMD. *McCurnin's Clinical Textbook for Veterinary Technicians*, 9th Edition. Pg 849.
Mosby's Comprehensive Review for Veterinary Technicians 5th Edition. Pg 673.

Question: 17

Which type of scissors should be used to remove a bandage from a canine patient?

- A .Metzenbaum scissors
- B. Mayo scissors
- C. Carless scissors
- D.Lister scissors

Answer: D

Explanation:

Lister scissors are generally used to cut bandages. The tip of the lower blade features a flattened blunt nodule intended to slide between bandages and skin without cutting the skin.

Carless scissors are used for cutting sutures.

Mayo scissors are used for dense soft tissues.

Metzenbaum scissors are used for delicate dissections.



Reference:

Joanna M. Bassert, VMD. *McCurnin's Clinical Textbook for Veterinary Technicians, 9th Edition*. Pg 1068.
Mosby's Comprehensive Review for Veterinary Technicians 5th Edition. Pg 528.

Question: 18

High levels of glucose in urine can indicate which disease process?

- A. Diabetes mellitus
- B. Hypoadrenocorticism
- C .Lymphoma
- D. Diabetes insipidus

Answer: A

Explanation:

High levels of glucose in urine can indicate diabetes mellitus. Diabetes is a disorder of insulin deficiency or resistance, resulting in elevated blood glucose as the cells starve. Eventually, the kidneys cannot filter back all blood glucose and some spills over into the urine. Glucose is not found in the urine under normal circumstances.

Glucosuria is not associated with hypoadrenocorticism, diabetes insipidus, or lymphoma.

Reference:

Joanna M. Bassert, VMD. *McCurnin's Clinical Textbook for Veterinary Technicians, 9th Edition*. Pg 400.

Mosby's Comprehensive Review for Veterinary Technicians 5th Edition. Pg 31-32.

Question: 19

What is the medical term for the bottom/lower jaw?

- A. Bulla
- B. Zygomatic arch
- C. Maxilla
- D. Mandible

Answer: D

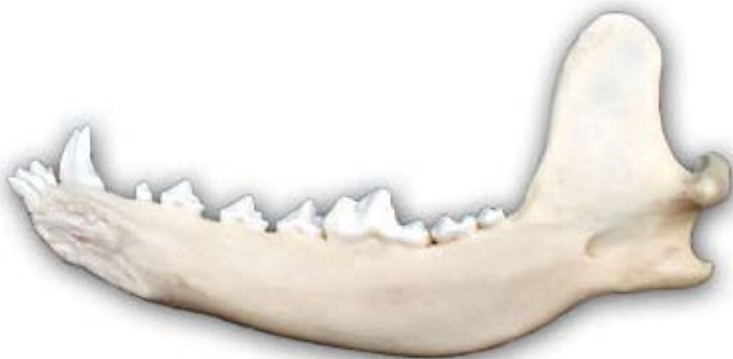Explanation:

The mandible is formed from two bones that form the horseshoe-shaped lower jaw. The caudal mandibles articulate with the temporal bones of the skull at the temporomandibular joint. Rostrally, the two bones are joined by a cartilaginous joint called the mandibular symphysis.

The maxilla is composed of numerous bones that form the upper jaw and palate.

The bullae (also called tympanic bullae) are hollow bone structures found on the caudoventral skull and enclose portions of the middle and inner ear.

The zygomatic arches form part of the orbits for the eyes and are easily palpable as the "cheekbones."



Reference:

Clinical Anatomy and Physiology for Veterinary Technicians 3rd Edition. Pg 184-187.

Question: 20

What is a hemothorax?

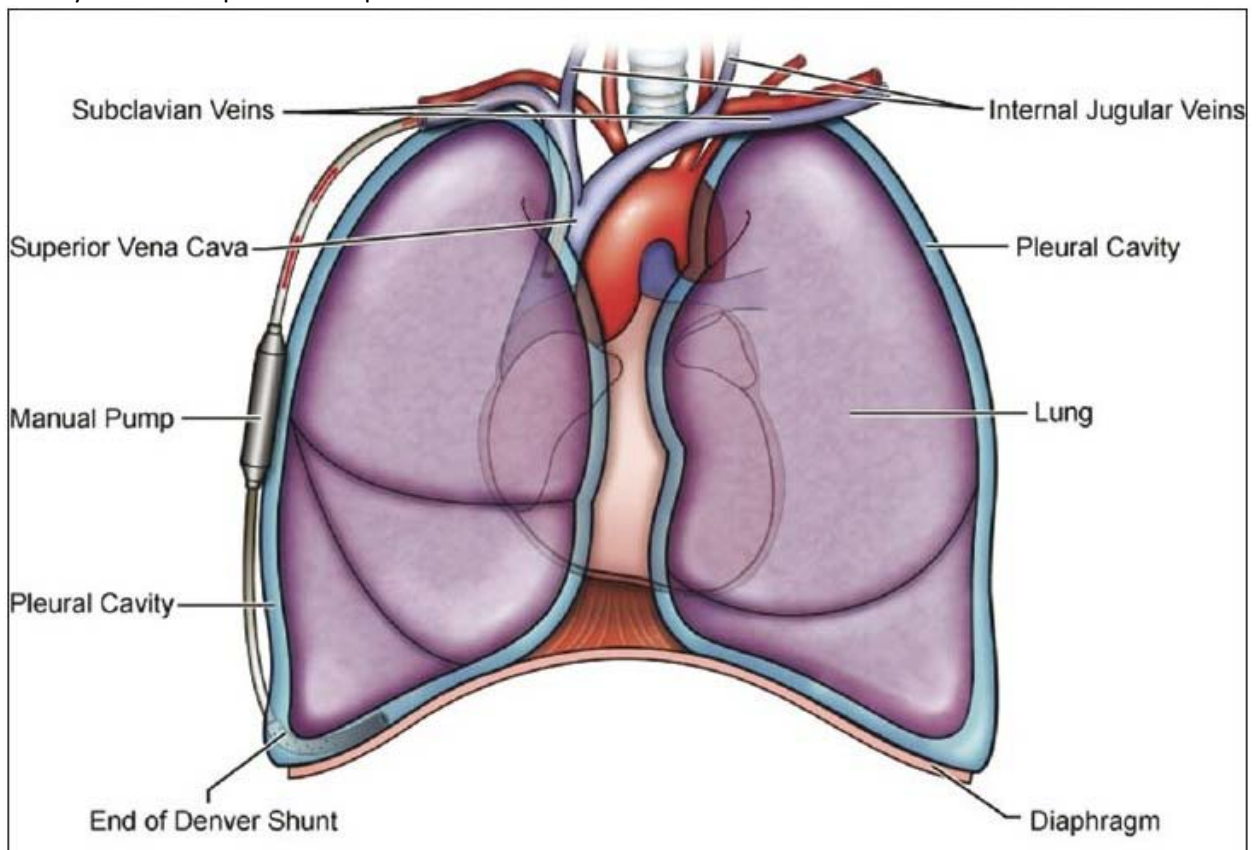
- A. Accumulation of blood in the pleural cavity
- B. Accumulation of blood in the urinary bladder
- C. Accumulation of blood and air in the peritoneal space
- D. Accumulation of urine in the pleural space

Answer: A

Explanation:

Hemothorax is the accumulation of blood in the pleural cavity. This is often a result of severe trauma and requires the placement of chest tubes to drain the blood.

A hemothorax is not the accumulation of urine in the pleural space, nor the accumulation of blood in the urinary bladder or peritoneal space.



Reference:

Clinical Anatomy and Physiology for Veterinary Technicians 3rd Edition. Pg 133.

For More Information – **Visit link below:**
<http://www.certsgrade.com/>

PRODUCT FEATURES

-  **100% Money Back Guarantee**
-  **90 Days Free updates**
-  **Special Discounts on Bulk Orders**
-  **Guaranteed Success**
-  **50,000 Satisfied Customers**
-  **100% Secure Shopping**
-  **Privacy Policy**
-  **Refund Policy**

Discount Coupon Code: **CERTSGRADE10**

